

## Evaluating the Proposed Mechanism by Which Atorvastatin Can Protect Renal Tissue against Contrast Media: An Animal study

Samer Jaffar Sharif \*, Bahir Abdul Razzaq Mshimesh\*, Ahmed Fakhir Hameed\*\*,  
Suzan Yousif Jasim\*\*\*

\**Department of Pharmacology and Toxicology, College of Pharmacy, Mustansiriyah University, M.Sc. program, Iraq.*

\*\* *Department of Anatomy and Histology, College of Medicine, Mustansiriyah University, Baghdad- Iraq.*

\*\*\* *Department of Clinical Laboratory Sciences, College of Pharmacy, Mustansiriyah University, Baghdad- Iraq.*

DOI: <https://doi.org/10.32947/ajps.19.01.0395>

### Article Info:

Received 2 Jan 2019

Accepted 24 Feb 2019

Published 1 Mar 2019

Corresponding Author email:

dr.bahirrazzaq@uomustansiriyah.edu.iq

orcid: <https://orcid.org/0000-0003-4421-8690>

### Abstract:

Contrast- induced nephropathy (CIN) is an elevation of serum creatinine of  $\geq 0.5$  mg/dL from baseline after two to three days of exposure to contrast substance if there is no other cause for acute kidney injury. Atorvastatin may protect normal kidney physiology from contrast- induced

kidney injury by effects unrelated to hypolipidemia termed pleiotropic effect by decline of endothelin production, angiotensin system down regulation, and under expression of endothelial adhesion molecules. This study was conducted to assess the strategy by which atorvastatin can achieve protective effect for kidneys after exposure to contrast media in an animal model. A 40 male rats were distributed randomly into 4 groups; ten rats for each: group (1): given normal saline; group (2): CIN group given iopromide as contrast media; group (3): given atorvastatin (20mg/kg) and iopromide; and group (4): given atorvastatin (40mg/kg) and iopromide. Blood collected by cardiac puncture for detection of serum glutathione, malondialdehyde, matrix metalloproteinase-9, and interleukin-18. The results have shown a significant increase in inflammatory and oxidative stress markers in contrast media group, and significant reduction in these markers in atorvastatin treated groups, in a dose-dependent manner. As conclusion, atorvastatin mechanism for protection against CIN in a dose-dependent manner can mediate by anti-inflammatory and antioxidant effects.

**Key words:** contrast induced nephropathy, atorvastatin, oxidative stress, inflammation.

تقييم الآلية المحتملة لعقار الأتورفستاتين في الحماية من تضرر الأنسجة الكلوية المستحث بواسطة صبغات التباين: دراسة في الحيوانات المختبرية

سامر جعفر شريف\*, باهر عبد الرزاق مشميش\*, أحمد فاخر حميد\*\*, سوزان يوسف جاسم\*\*\*  
\*فرع الأدوية والسموم/كلية الصيدلة/الجامعة المستنصرية  
\*\* فرع الأنسجة والتشريح/كلية الطب/الجامعة المستنصرية  
\*\*\* فرع العلوم المختبرية السريرية/كلية الصيدلة/الجامعة المستنصرية

## الخلاصة:

إعتلال الكلى الناجم عن التباين يعرف بأنه زيادة في كرياتينين المصل  $\leq 0.5$  ملغ / ديسيلتر من خط الأساس في 2-3 أيام بعد التعرض لعامل التباين في غياب أسباب أخرى لإصابة الكلى الحادة. قد يحمي أتورفاستاتين، وهو عامل تخفيض للدهون، وظائف الكلى من الإصابة الحادة الناتجة عن التباين عن طريق تأثيرات أخرى لاتتعلق بمستويات الدهون التي يطلق عليها تأثيرات عديد المظاهر، مثل تقليل تخليق الاندوثيلين، ومستقبلات الأنجيوتنسين، والتعبير عن جزيئات الالتصاق البطاني.

أجريت هذه الدراسة لتقييم الآليات التي من خلالها يمكن أن يحمي أتورفاستاتين الأنسجة الكلوية ضد وسائل التباين في ذكور الفئران. تم تقسيم أربعين من ذكور جرذان الويستر بشكل عشوائي إلى أربع مجموعات. كل مجموعة تحتوي على عشرة جرذان. المجموعة الأولى: تلقت محلول ملحي طبيعي. المجموعة الثانية: مجموعة إعتلال الكلى الناجم عن التباين تلقت إيبرومايد كوسط متباين. المجموعة الثالثة: تلقت أتورفاستاتين (20 مغ/كغ) ووسائط تباين. المجموعة الرابعة: تلقت أتورفاستاتين (40 مغ/كغ) ووسائط تباين. تم جمع عينات الدم عن طريق ثقب في القلب للكشف عن الجلوتاثيون المصلي، مالون داي الدهايد، مصفوفة ميتالوبروتينيس 9-، و انترلوكين-18.

أظهرت النتائج زيادة كبيرة في علامات الإجهاد والأكسدة في مجموعة عوامل التباين وإنخفاض كبير في هذه العلامات في المجموعات التي عولجت بالأتورفاستاتين بطريقة تعتمد على الجرعة.

مما تقدم يمكن الإستنتاج أن عقار الأتورفاستاتين يعمل كمادة وقائية لمنع إعتلال الكلى الناجم عن التباين بطريقة تعتمد على الجرعة، من خلال التأثيرات المضادة للإلتهابات ومضادات الأكسدة.

**الكلمات المفتاحية:** صبغات التباين، إعتلال الكلى، أتورفاستاتين، الجهد التأكسدي، الإلتهاب.

## Introduction:

Contrast media (CM) is an agent that is used to enhance visibility of body tissues, usually used for blood vessels and GI organs<sup>[1]</sup>. Different types of contrast media are used in several techniques according to imaging devices, where they are used in<sup>[2]</sup>: X-ray technique; magnetic resonance imaging (MRI) signal enhancing; and ultrasound scattering. Contrast media may be negative or positive, this difference is related to absorbing fewer or more of the radiation than do the neighboring tissues, respectively<sup>[3]</sup>.

Iodinated contrast agent is a form of intravenous radiocontrast having iodine, which improves the visibility of structures and organs during radiographic procedures. Usually, an iodinated contrast agent may either be oil-based or water-soluble. The oil-based is slowly absorbed by body tissue and, it is usually only used in sialographic and hysterosalpingographic studies. Water-soluble iodinated medium, which is more rapidly absorbed, may be used in place of barium sulfate for gastrointestinal examination that is contraindicated by the use of barium<sup>[4]</sup>.

Iopromide is used as a water-soluble x-ray contrast agent. It is low osmolar, non-ionic contrast agent for intravascular use. It makes opaque when passing in the vessels under x-ray path, permitting imaging of internal tissues and structures. The levels of opaqueness caused by iodine materials is related directly to the quantity of iodine in contrast media (volume and concentration)<sup>[5]</sup>.

Fatal anaphylactoid or life-threatening reactions may occur throughout or after iopromide administration. These responses range from itching, urticaria, bronchospasm, to facial and laryngeal edema<sup>[6]</sup>. Iodinated contrast agent has a toxic effect on the kidneys, particularly when given by arteries, during coronary angiography<sup>[7]</sup>. Contrast-induced nephropathy (CIN) is an elevation of serum creatinine of  $\geq 0.5$  mg/dL or  $\geq 25\%$  from baseline after two to three days of exposure to contrast substance if there is no other cause for acute kidney injury<sup>[8,9]</sup>.

The pathophysiology of CIN not completely understood yet. Many issues may play an important role in the mechanism of this type of kidney damage.

These factors include indirect insult, e.g. increase renal vasoconstriction, depletion of prostaglandin formation and decrease nitric oxide; also involve the direct injury on renal tubules by free radicals' generation, more oxygen consumption, and increase internal pressure because of tubular obstruction. All these situations end with ischemia of medullary region of the kidney<sup>[10]</sup>.

Many risk factors may enhance the attack with CIN; some of them related to patient and other with procedure itself such as types of contrast media, dose and multiple contrast media administration within 72 hours. Patient related risk factors are more important and involve: aging; heart failure; hypotension; hyperglycemia; hypo-albuminemia; renal impairment; nephrotoxic agents; and others<sup>[11]</sup>. As prevention strategies against CIN, intravenous extracellular volume expansion with saline, using lowest dose of contrast media, and administering low osmolar non-ionic contrast media instead of high osmolar ionic type reported some effectiveness<sup>[12]</sup>. Like other statins, atorvastatin is a competitive inhibitor of 3-hydroxy-3-methyl-glutaryl-coenzyme A reductase inhibitor. It's used in the prevention of cardiovascular diseases in elderly patients, with high risk for coronary heart diseases, such as hypertension, age  $\geq 55$  years, low HDL- cholesterol, smoking, or history of family coronary heart disease.<sup>[13]</sup>

Atorvastatin have "pleiotropic effects" antioxidant properties, by reducing reactive oxygen species (ROS) generation and lipid peroxidation. This effect mediated by decrease production of important isoprenoids intermediates (geranylgeranyl pyrophosphate and farnesyl pyrophosphate)<sup>[14]</sup>. The anti-inflammatory effect of atorvastatin in rheumatoid conditions mediated by inhibitory effect on several proinflammatory cytokines such as interleukin-1 $\beta$  (IL-1 $\beta$ ), interleukin-6 (IL-6), tumor necrosis factor- $\alpha$  (TNF- $\alpha$ ), and chemokines (CCL2, CCL5) which were reduced

significantly in treated arthritic rats by atorvastatin<sup>[15]</sup>.

This study was conducted to assess the mechanism by which atorvastatin can achieve protective effect against kidney damage after exposure to contrast media in an animal model.

## Materials and Methods

### Animals

Forty male rats (200-300g) were involved in this study and placed in animal house in College of Pharmacy/Mustansiriyah University, feed on pellets and free water. With animals placed in cages each plastic cage (20 $\times$ 25 $\times$ 35cm) contains 3 rats. Animals left a week for environmental acclimatization, temperature (23 $\pm$ 3 °C), 12/12 hr light/dark rhythm. The study approved from ethics and scientific committee/College of Pharmacy/Mustansiriyah University, this experiment was start.

### Experimental Protocol

Rats distributed randomly to 4 groups, ten for each:

Group (1): given saline orally for 6 days, as control.

Group (2): CIN group; exposed to dehydration 3 days, in 4<sup>th</sup> day given furosemide (10mg/kg) as intramuscular, 20 min later iopromide 370 mg I/ml given IV through tail vein as 10 ml/kg<sup>[16]</sup>.

Group (3): small-dose atorvastatin group; given atorvastatin (20mg/kg)<sup>[17]</sup> over 6 consecutive days, exposed to dehydration between day 2 to 4, in 5<sup>th</sup> day furosemide (10mg/kg) given through IM, 20 min later iopromide 370 mg I/ml given IV via tail vein as 10 ml/kg.

Group (4): large-dose atorvastatin group; like with third group but atorvastatin given in 40 mg/kg.

Regarding atorvastatin preparation, a 40 mg of calcium salt as white crystalline powder was dissolved in 5 ml DW to obtain oral suspension (8 mg/ml).

### Collection of Samples

Within the 7<sup>th</sup> day and after anaesthetizing each animal by ketamine and xylazine [18], we collect blood specimen via intracardiac aspiration, each sample was transferred to plastic centrifuge tube and left at room temperature for complete clotting of blood. Serum was aspirated after centrifugation at 1000 rpm for 10 minutes and kept in the freeze to be ready for doing assay of serum glutathione, malondialdehyde, matrix metalloproteinase-9, and interleukin-18.

### Assay of Biomarkers

Detection of serum glutathione (GSH), malondialdehyde (MDA), matrix metalloproteinase-9 (MMP-9), and interleukin-18 (IL-18) were measured by sandwich ELISA technique according to the manufacturer's instructions (Mybiosource-USA) [19].

### Statistical Analysis

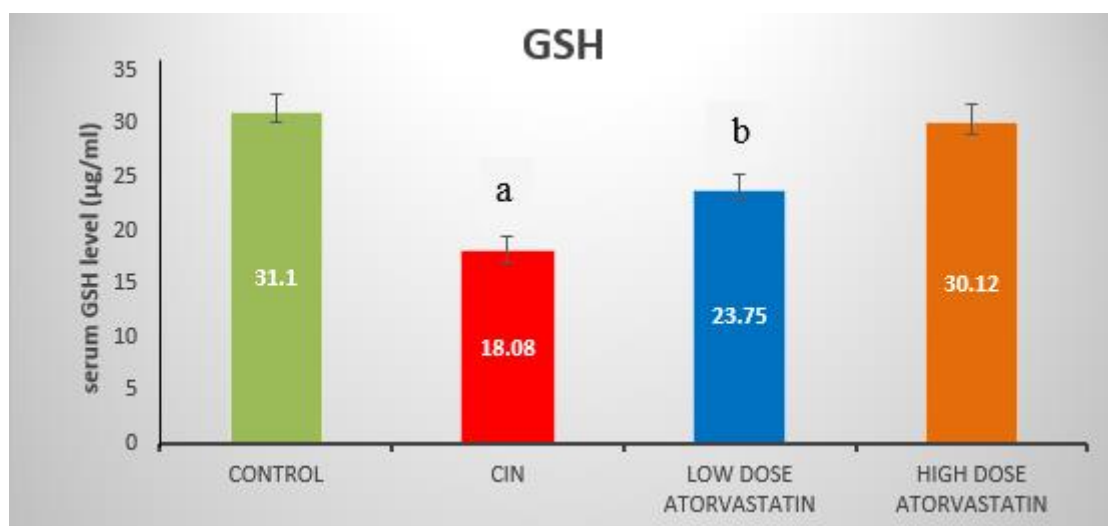
Data were expressed as mean  $\pm$  SD and the ANOVA test was used for statistical evaluation of significant difference among groups and compared with that of control, using SPSS-16 software program. P-value of  $< 0.5$  was regarded as significant.

### Results

#### Effect of Atorvastatin on Oxidative Stress Markers After Contrasting Induced Nephropathy

Regarding oxidative stress markers, GSH levels reduced significantly in CIN group compared with other groups ( $p < 0.05$ ). Low dose atorvastatin group elevated GSH levels significantly compared with CIN group, but still significantly lower than control group and high dose atorvastatin group ( $p < 0.05$ ). High dose atorvastatin significantly increased GSH levels compared with low dose atorvastatin and CIN groups ( $p < 0.05$ ) and approach to control group ( $p = 0.664$ ), as shown figure (1).

Considering serum MDA marker, its levels increased significantly in CIN group compared with other groups ( $p < 0.05$ ). Low dose atorvastatin group reduced MDA levels significantly compared with CIN group, but still significantly higher than control group and high dose atorvastatin group ( $p < 0.05$ ). High dose atorvastatin significantly reduced MDA levels compared with low dose atorvastatin and CIN groups ( $p < 0.05$ ) and approach to control group ( $p = 0.926$ ), as shown figure (2).



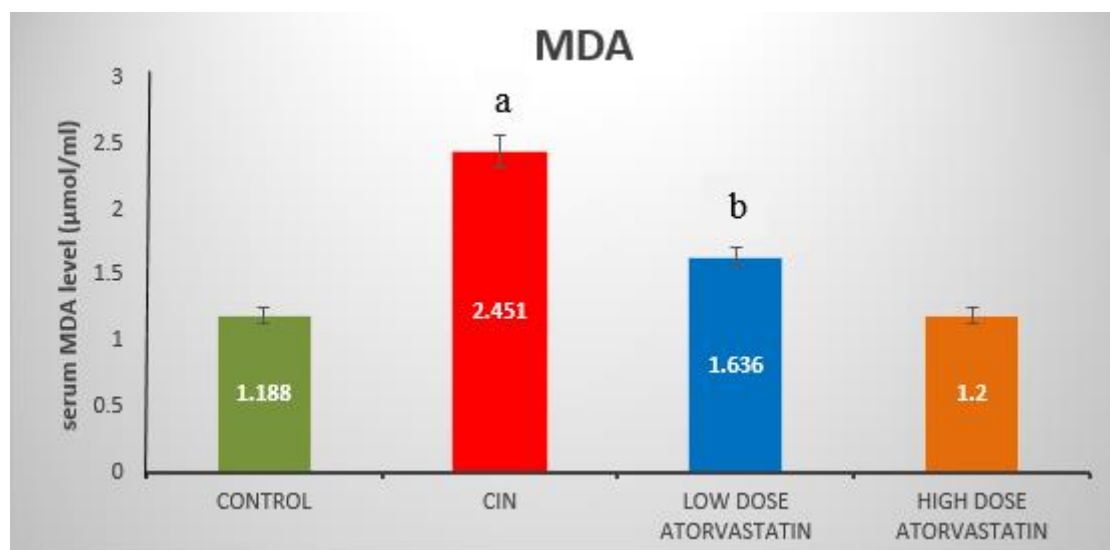
**Figure (1): Effect of atorvastatin on serum GSH levels after CIN.**

Data were expressed as  $M \pm SEM$ .

Different lower-case letters indicate significant difference among groups.

$P$ -value < 0.05 considered significant difference.

GSH= Glutathione, CIN= contrast induced nephropathy.



**Figure (2): Effect of Atorvastatin on Serum MDA Levels After CIN.**

Data were expressed as  $M \pm SEM$ .

Different lower-case letters indicate significant difference among groups.

$P$ -value < 0.05 considered significant difference.

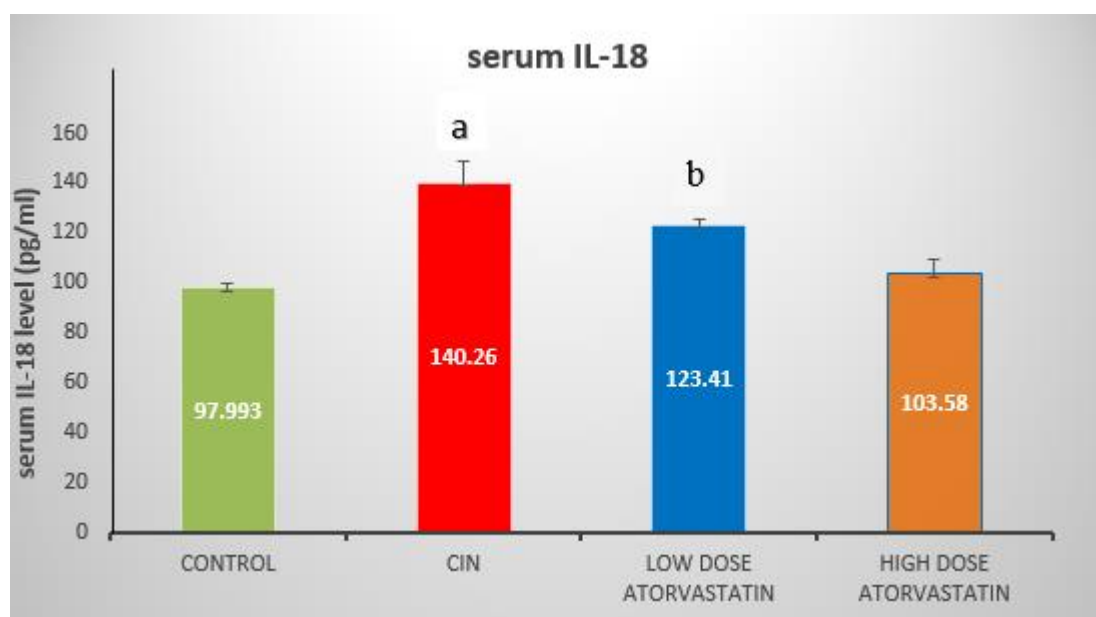
MDA= Malondialdehyde, CIN= contrast induced nephropathy.

#### **Effect of Atorvastatin on Inflammatory Markers After Contrasting Induced Nephropathy**

Regarding inflammatory markers, IL-18 levels increased significantly in CIN group compared with other groups ( $p < 0.05$ ). Low dose atorvastatin group reduced IL-18 levels significantly compared with CIN group, but still significantly higher than control group and high dose atorvastatin group ( $p < 0.05$ ). High dose atorvastatin significantly reduced IL-18 levels compared with low dose atorvastatin and CIN groups ( $p < 0.05$ ) and approach to

control group ( $p = 0.477$ ), as shown in figure (3).

Considering MMP-9 marker, its level increased significantly in CIN group compared with other groups ( $p < 0.05$ ). Low dose atorvastatin group reduced MMP-9 levels significantly compared with CIN group, but still significantly higher than control group and high dose atorvastatin group ( $p < 0.05$ ). High dose atorvastatin significantly reduced MMP-9 levels compared with low dose atorvastatin and CIN groups ( $p < 0.05$ ) and approach to control group ( $p = 0.868$ ), as shown figure (4).



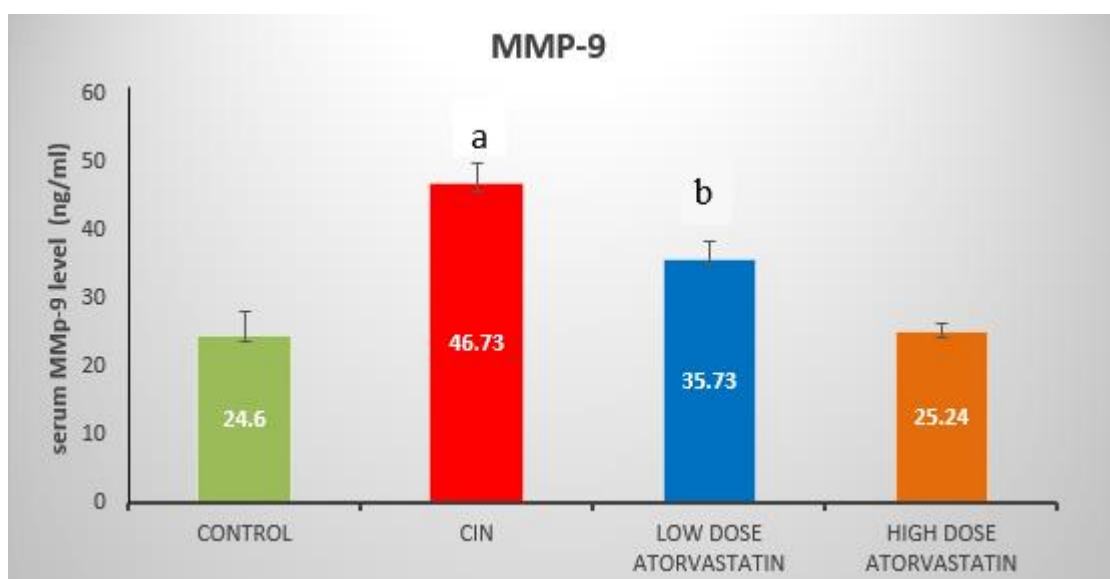
**Figure (3): Effect of Atorvastatin on IL-18 Levels After CIN.**

Data were expressed as  $M \pm SEM$ .

Different lower-case letters indicate significant difference among groups.

$P$ -value  $< 0.05$  considered significant difference.

IL-18= interleukin-18, CIN= contrast induced nephropathy.



**Figure (4): Effect of Atorvastatin on MMP-9 Levels After CIN.**

Data were expressed as  $M \pm SEM$ .

Different lower-case letters indicate significant difference among groups.

$P$ -value  $< 0.05$  considered significant difference.

MMP-9= Matrix Metalloproteinase-9, CIN= contrast induced nephropathy.

## Discussion

In normal physiological conditions, tubular transport related to ROS generation,

mostly in thick ascending limb, where high dense mitochondrial residents, which represents main sources for hydroxyl



readicals ( $\text{OH}^-$ ) and superoxide anions ( $\text{O}_2^-$ ) generation by NADPH- oxidase. In medullary tubular levels, ROS formation has a central role in regulating renal microcirculation, mediated its effect on NO bioavailability [20].

Contrast induced nephropathy results from combination of toxic renal parenchymal injury and hypoxia. Parenchymal injury result from ROS generation and renal hypoxia induced after iodinated contrast media administration increasing ROS generation in kidney [21].

Contrast media administration significantly decrease medullary oxygenation, without reduction in tubules reabsorption. As the result, neurohumoral vasoconstrictive changes mediated by increasing the release of endothelin and prostaglandin from endothelial cells when exposed to contrast media. All these lead to oxygen imbalance and reduces mitochondrial scavengers' activity and enhance ROS generation. During hypoxia conditions, high amount of ATP converted to ADP, AMP and adenosine which is further hydrolyzed to inosine by 5-nucleotidase and then metabolized to the hypoxanthine that generates hydrogen peroxide ( $\text{H}_2\text{O}_2$ ) and xanthine by xanthine oxidase enzyme. Hydrogen peroxide cause further damage to renal medullary microcirculation by scavenging NO. Also, superoxide redials reduced NO bioavailability by formation peroxynitrite, so in normal physiological conditions, NO protect against ROS-mediated endothelial injury and diminished transport-dependent ROS generation in the thick ascending limbs [21].

Previous studies have shown that oxidative stress and generation of free radicals after exposure to contrast media have an important role in pathogenesis of CIN and reduced antioxidant enzymes activity (i.e. shift the balance from antioxidant toward the oxidative stress) [22,23].

In the current study, serum GSH levels significantly decreased after exposure to contrast media, while treated atorvastatin groups show significant rise in GSH levels

in a dose-dependent manner by 32% and 66.6% in low and high dose respectively, compared with CIN group.

These results were similar to the Al-Otaibi *et al* findings (2012), who found that levels of GSH in renal tissues markedly decreased after exposure to contrast media while treatment with simvastatin reversed the effect of contrast media significantly in a dose dependent-manner [24] and agree with Cusumano *et al* study (2015), who was demonstrated that high dose of atorvastatin has protective effect against inflammation and oxidative stress in ischemia-reperfusion injury of kidney in animal model, also he reported that atorvastatin increase antioxidant enzymes activity of glutathione peroxidase and catalase and inhibit myeloperoxidase [25] and consist with El-Moseelhy *et al* study (2014), who was reported that treatment with atorvastatin significantly increased GSH and catalase levels, compared with doxorubicin group which cause renal toxicity [26].

In the present study, serum MDA levels significantly raised after exposure to contrast media in CIN group, while treatment with atorvastatin significantly reversed the elevated levels of this marker and reduced it by 33% and 51% in low and high dose respectively, compared with CIN group.

These results match with wang *et al* study (2017), who was reported that serum MDA level markedly increased in contrast induced acute kidney injury group, while treatment with atorvastatin and rosuvastatin significantly decrease this marker levels [27] and consist with Deng *et al* results (2015), who had demonstrated that treatment with rosuvastatin notably lowered serum MDA levels in CIN animal model [28] and also match with Cao *et al* findings (2012), who was shown in clinical study that pretreatment with high dose of atorvastatin was more effective in reducing oxidative stress and incidence of CIN in patients undergo percutaneous coronary interventions [29].

The main hypothesis of pathogenesis in CIN is local ischemia-reperfusion renal tubules. Interleukin-18 (IL-18) expressed in proximal tubule and activated by caspase-1 during renal ischemia. So, IL-18 can be used for diagnosis of ischemic renal injury in CIN during 24-48 hours [30].

Interleukin-18 is a pro-inflammatory cytokine, its a member of IL-1 cytokine superfamily, describe as important regulator for acquired and innate immune response. It is expressed or induced in autoimmune diseases, sites of acute and chronic inflammation, and infectious diseases [31].

In the current study, serum IL-18 levels were markedly elevated in CIN group compared to control, while its level significantly reduced in low and high dose atorvastatin group by 12% and 26% respectively, compared with CIN group.

These results agree with Zhao Kai *et al* study (2015), who had found that Dongchongxiacao (a herbal Chinese with antioxidant effects) decrease urinary IL-18 levels in CIN by attenuating renal microvessels injury through activating superoxide dismutase[32] and disagree with Jin Ha Park *et al* study (2016), who had demonstrated that atorvastatin couldn't lower the incidence of acute kidney injury and serum IL-18 levels in patient undergo valvular heart surgery [33].

Matrix metalloproteinase (MMP) is family of enzymes involved in degradation of the extracellular matrix, it is always present in human tissues in which inflammation occur. The member of MMPs have different roles in normal and pathological inflammatory developments, it act during inflammation to activate cytokines and chemokines and generate of chemokine gradients [34]. WK Han *et al* (2008) reported that urinary levels of MMP-9 can be used to detect acute renal injury before serum creatinine elevation, he found that urinary MMP-9 concentration in patients with acute kidney injury was significantly higher than patient with chronic renal disease [35]. Also, Van der Zijl *et al* (2010)

demonstrated that levels of MMP-9 in diabetic patients related to the stage of diabetic nephropathy, compared with normal human [36].

In this study, serum MMP-9 levels markedly reduced in low and high doses of atorvastatin by 23.5% and 46% respectively, compared with CIN group. These results were similar to Yao *et al* results (2010), who reported that simvastatin have potential therapeutic effect in diabetic nephropathy of animal model by down regulating the expression of MMP-9 in renal tissues [37].

The anti-inflammatory properties of atorvastatin depend on the Ras prenylation inhibition. Ras inhibition reduce nuclear factor kappa-B (NF $\kappa$ B) activity involved in various inflammatory pathways and has a central role in atherosclerotic pathology. Atorvastatin reduced the activity of dimer for c-Jun, activator protein 1, and transcriptional factor which have a central role in regulating genes of MMPs, adhesion molecules, endothelial inflammatory response, inducible nitric oxide synthase, chemokines, cytokines, and Fas ligand. Also, atorvastatin induce hypoxia inducible factor 1 $\alpha$  (HIF1 $\alpha$ ), which was decreased by TNF- $\alpha$  in endothelial cells [38].

## Conclusion

As conclusion, atorvastatin mechanism for protection against CIN in a dose-dependent manner can mediate by anti-inflammatory and antioxidant effects.

## Acknowledgments

The authors would like to thank Mustansiriyah University College of pharmacy (www.uomustansiriyah.edu.iq), Baghdad-Iraq, for its support in the present work.

## References:

- 1- Dorland's medical reference works. In: Wikipedia [Internet]. 2017 [cited 2018 Aug 1]. Available from: <https://en.wikipedia.org/w/index.php?t>



- itle=Dorland%27s\_medical\_reference\_works&oldid=784621111
- 2- Beckett KR, Moriarity AK, Langer JM. Safe Use of Contrast Media: What the Radiologist Needs to Know. *RadioGraphics*. 2015 Oct 1; 35(6): 1738–50.
- 3- Herrtage ME, Dennis R. BSAVA Education Committee Commissioned Article Contrast media and their use in small animal radiology. *J Small Anim Pract*. 1987 Dec 1;28(12):1105–14.
- 4- Lusic H, Grinstaff MW. X-ray-Computed Tomography Contrast Agents. *Chem Rev*. 2013 Mar 13;113(3):1641–66.
- 5- Pasternak JJ, Williamson EE. Clinical Pharmacology, Uses, and Adverse Reactions of Iodinated Contrast Agents: A Primer for the Non-radiologist. *Mayo Clin Proc*. 2012 Apr;87(4):390–402.
- 6- Bottinor W, Polkampally P, Jovin I. Adverse Reactions to Iodinated Contrast Media. *Int J Angiol Off Publ Int Coll Angiol Inc*. 2013 Sep;22(3):149–54.
- 7- McDonald RJ, McDonald JS, Carter RE, Hartman RP, Katzberg RW, Kallmes DF, et al. Intravenous Contrast Material Exposure Is Not an Independent Risk Factor for Dialysis or Mortality. *Radiology*. 2014 Sep 9;273(3):714–25.
- 8- McCullough PA. Contrast-Induced Acute Kidney Injury. *J Am Coll Cardiol*. 2008 Apr 15;51(15):1419–28.
- 9- Mehran R, Nikolsky E. Contrast-induced nephropathy: Definition, epidemiology, and patients at risk. *Kidney Int*. 2006 Apr 1;69: S11–5.
- 10- Jorgensen AL. Contrast-Induced Nephropathy: Pathophysiology and Preventive Strategies. *Crit Care Nurse*. 2013 Jan 2;33(1):37–46.
- 11- McCullough PA, Wolyn R, Rocher LL, Levin RN, O'Neill WW. Acute Renal Failure After Coronary Intervention: Incidence, Risk Factors, and Relationship to Mortality. *Am J Med*. 1997 Nov 1;103(5):368–75.
- 12- Toprak O. Risk Markers for Contrast-Induced Nephropathy. *Am J Med Sci*. 2007 Oct 1;334(4):283–90.
- 13- Lea AP, McTavish D. Atorvastatin. *Drugs*. 1997 May 1;53(5):828–47.
- 14- Profumo E, Buttari B, Saso L, Rigano R. Pleiotropic Effects of Statins in Atherosclerotic Disease: Focus on the Antioxidant Activity of Atorvastatin [Internet]. 2014 [cited 2018 Sep 18]. Available from: <https://www.ingentaconnect.com/content/ben/ctmc/2014/00000014/00000002/art00009>
- 15- Barsante MM, Roffê E, Yokoro CM, Tafuri WL, Souza DG, Pinho V, et al. Anti-inflammatory and analgesic effects of atorvastatin in a rat model of adjuvant-induced arthritis. *Eur J Pharmacol*. 2005 Jun 15;516(3):282–9.
- 16- Wang X, Zhang T, Hu L, Sun S, Zhang W, Sun Z, et al. Comparison of Effects of Different Statins on Contrast-Induced Acute Kidney Injury in Rats: Histopathological and Biochemical Findings [Internet]. *Oxidative Medicine and Cellular Longevity*. 2017 [cited 2018 Jul 16]. Available from: <https://www.hindawi.com/journals/omcl/2017/6282486/abs/>
- 17- He X, Li L, Tan H, Chen J, Zhou Y. Atorvastatin attenuates contrast-induced nephropathy by modulating inflammatory responses through the regulation of JNK/p38/Hsp27 expression. *J Pharmacol Sci*. 2016 May 1;131(1):18–27.
- 18- Van LP. Ketamine and xylazine for surgical anesthesia in rats. *J Am Vet Med Assoc*. 1977 Nov;171(9):842–4.
- 19- Gan SD, Patel KR. Enzyme immunoassay and enzyme-linked immunosorbent assay. *J Invest Dermatol*. 2013 Sep;133(9): e12.
- 20- Heyman SN, Rosen S, Khamaisi M, Idée J-M, Rosenberger C. Reactive

- Oxygen Species and the Pathogenesis of Radiocontrast-Induced Nephropathy. *Invest Radiol.* 2010 Apr;45(4):188.
- 21- Pisani A, Riccio E, Andreucci M, Faga T, Ashour M, Di Nuzzi A, et al. Role of Reactive Oxygen Species in Pathogenesis of Radiocontrast-Induced Nephropathy [Internet]. *BioMed Research International.* 2013 [cited 2018 Aug 18]. Available from: <https://www.hindawi.com/journals/bmri/2013/868321/abs/>
- 22- Seeliger E, Sendeski M, Rihal CS, Persson PB. Contrast-induced kidney injury: mechanisms, risk factors, and prevention. *Eur Heart J.* 2012 Aug 1;33(16):2007–15.
- 23- Quintavalle C, Brenca M, Micco FD, Fiore D, Romano S, Romano MF, et al. In vivo and in vitro assessment of pathways involved in contrast media-induced renal cells apoptosis. *Cell Death Dis.* 2011 May;2(5): e155.
- 24- Al-Otaibi KE, Al Elaiwi AM, Tariq M, Al-Asmari AK. Simvastatin attenuates contrast-induced nephropathy through modulation of oxidative stress, proinflammatory myeloperoxidase, and nitric oxide. *Oxid Med Cell Longev.* 2012; 2012:831748.
- 25- Cusumano G, Romagnoli J, Liuzzo G, Ciavarella LP, Severino A, Copponi G, et al. N-Acetylcysteine and High-Dose Atorvastatin Reduce Oxidative Stress in an Ischemia-Reperfusion Model in the Rat Kidney. *Transplant Proc.* 2015 Nov 1;47(9):2757–62.
- 26- El-Moselhy MA, El-Sheikh AAK. Protective mechanisms of atorvastatin against doxorubicin-induced hepatorenal toxicity. *Biomed Pharmacother.* 2014 Feb 1;68(1):101–10.
- 27- Wang X, Zhang T, Hu L, Sun S, Zhang W, Sun Z, et al. Comparison of Effects of Different Statins on Contrast-Induced Acute Kidney Injury in Rats: Histopathological and Biochemical Findings [Internet]. *Oxidative Medicine and Cellular Longevity.* 2017 [cited 2018 Jul 24]. Available from: <https://www.hindawi.com/journals/omcl/2017/6282486/abs/>
- 28- Deng J, Wu G, Yang C, Li Y, Jing Q, Han Y. Rosuvastatin attenuates contrast-induced nephropathy through modulation of nitric oxide, inflammatory responses, oxidative stress and apoptosis in diabetic male rats. *J Transl Med.* 2015 Feb 12; 13:53.
- 29- Cao S, Wang P, Cui K, Zhang L, Hou Y. [Atorvastatin prevents contrast agent-induced renal injury in patients undergoing coronary angiography by inhibiting oxidative stress]. *Nan Fang Yi Ke Da Xue Xue Bao.* 2012 Nov;32(11):1600–2.
- 30- He H, Li W, Qian W, Zhao X, Wang L, Yu Y, et al. Urinary interleukin-18 as an early indicator to predict contrast-induced nephropathy in patients undergoing percutaneous coronary intervention. *Exp Ther Med.* 2014 Oct 1;8(4):1263–6.
- 31- Gracie JA, Robertson SE, McInnes IB. Interleukin-18. *J Leukoc Biol.* 2003 Feb;73(2):213–24.
- 32- Kai Z, Yongjian L, Sheng G, Yu L. Effect of Dongchongxiacao (Cordyceps) therapy on contrast-induced nephropathy in patients with type 2 diabetes and renal insufficiency undergoing coronary angiography. *J Tradit Chin Med.* 2015 Aug 15;35(4):422–7.
- 33- Park JH, Shim J-K, Song J-W, Soh S, Kwak Y-L. Effect of atorvastatin on the incidence of acute kidney injury following valvular heart surgery: a randomized, placebo-controlled trial. *Intensive Care Med.* 2016 Sep 1;42(9):1398–407.
- 34- Manicone AM, McGuire JK. Matrix metalloproteinases as modulators of inflammation. *Semin Cell Dev Biol.* 2008 Feb 1;19(1):34–41.

- 35- Han WK, Waikar SS, Johnson A, Betensky RA, Dent CL, Devarajan P, et al. Urinary biomarkers in the early diagnosis of acute kidney injury. *Kidney Int.* 2008 Apr 1;73(7):863–9.
- 36- van der Zijl NJ, Hanemaaijer R, Tushuizen ME, Schindhelm RK, Boerop J, Rustemeijer C, et al. Urinary matrix metalloproteinase-8 and -9 activities in type 2 diabetic subjects: A marker of incipient diabetic nephropathy? *Clin Biochem.* 2010 May 1;43(7):635–9.
- 37- Yao XM, Ye SD, Zai Z, Chen Y, Li XC, Yang GW, et al. Simvastatin protects diabetic rats against kidney injury through the suppression of renal matrix metalloproteinase-9 expression. *J Endocrinol Invest.* 2010 May 1;33(5):292–6.
- 38- Blum A, Shamburek R. The pleiotropic effects of statins on endothelial function, vascular inflammation, immunomodulation and thrombogenesis. *Atherosclerosis.* 2009 Apr 1;203(2):325–30.