

Nitro BlueTetrazolium Chloride and Phagocytic Activity for Entamoeba Histolytica

Zaid Habeeb Abd-Alkareem*, Jaber Hameed Hussain**, Huda Jaber Waheed***

* Pharmacist in M.O.H Wasit health

** Al-Esraa University

***College of Pharmacy, Al-Mustansiriyah University, Iraq.

DOI: <https://doi.org/10.32947/ajps.19.04.0419>

Article Info:

Received 12 Mar 2019

Accepted 15 Sep 2019

Published 1 Nov 2019

Corresponding Author email:

Dr.huda.ja@uomustansiriyah.edu.iq

orcid: <https://orcid.org/0000-0001-8491-8334>

Abstract:

Background: The NBT consist from two tetrazole molecules consider as the oxidative substance. The quantitative NBT test under standard conditions the leucocyte readiness is brooded together with NBT under standard conditions and declining of the color quantitated after extraction into pyridine is exceptionally valuable in the analysis by Spectro-

photometry Entamoeba histolytica parasite induces apoptosis in host cells by for step(first)adherence to the host cell surface, (second) contact-subordinate cell killing, (third) start of phagocytosis so NBT used to determine percentage of phagocytosis for Entamoeba. Methods: This study was performed on 80 male they were divided to 25 control subjects and 55 subjects were diagnosed to be infected by Entamoeba histolytica at urban and rural areas in wassit province. Entamoeba histolytica and NBT were evaluated. Results: The results showed a significant difference between the two groups (10.96 ± 2.745) for control group and 19.63 ± 3.617 in patients' group with confidence interval (7.056-10.29). P.value $P < 0.001$ ratio minimum number was 7%, 13% for the control and patient groups. Conclusion: There were a significant increase in phagocytic activity of polymorph neaucler neutrophils (PMNs) for reduction of NBT stain

Key words: NBT, Entamoeba histolytica

صبغة نيترو تترازانيوم الزرقاء ونشاط البلعمة لإنتاموبيا هيستوليتيكا

زيد حبيب عبد الكريم*, جابر حميد حسين**, هدى جابر وحيد***

* وزارة الصحة دائرة صحة واسط

** كلية الاسراء الجامعة

*** كلية الصيدلة الجامعة المستنصرية

الخلاصة:

الخلفية: يتكون NBT من جزيئين التترازول يعتبران المادة المؤكسدة. يعد اختبار NBT الكمي في ظل ظروف قياسية هو تحضير استعداد الكريات البيض مع NBT في ظل ظروف قياسية ، كما أن انخفاض اللون المقدر بعد الاستخراج إلى البيريدين له قيمة استثنائية في التحليل عن طريق القياس الطيفي لطفيليات التحاليل الخلوية المستحثة للطفيليات في الخلايا المضيفة عن طريق الخطوة (الأولى) التمسك بسطح الخلية المضيفة ، (ثانياً) قتل الخلايا التلامسية-الثانوية ، (ثالثاً) بداية البلعمة حتى يستخدم NBT لتحديد النسبة المئوية لعدوى البلعمة لإنتاموبيا. الطريقة: أجريت هذه الدراسة على ٨٠ ذكراً تم تقسيمهم إلى ٢٥ شخصاً خاضعاً للمراقبة ، وتم تشخيص ٥٥ شخصاً على أنهم مصابون بالنسج المطاحن في المناطق الحضرية والريفية في محافظة واسط. تم تقييم Entamoeba histolytica و NBT. النتائج: أظهرت النتائج وجود اختلاف كبير بين المجموعتين (10.96 ± 2.745) لمجموعة المراقبة و 19.63 ± 3.617 في مجموعة المرضى الذين يعانون من فاصل الثقة ($7.056-10.29$). كان $P < 0.001$ نسبة الحد الأدنى لعدد ٧ % ، ١٣ % للمجموعات

السيطرة والمريض. الخلاصة: كانت هناك زيادة كبيرة في نشاط البلعمة من العدلات (PMNs) (polymorph neaucler) للحد من وصمة عار NBT الكلمات المفتاحية: صبغة نيترو تترازانيوم الزرقاء , لإنتاموبيا هيستوليتيكا

Introduction

Entamoeba histolytica was firstly defined as an amebiasis by Russian searcher named Fedor Losch in 1875 in city called San Petersburg. Fritz Schaudinn in 1903 described and named *Entamoeba histolytica* (1). It is an anaerobic parasitic protozoan and commonly it infects the Gastrointestinal tract of humans or other primates (2). The *Entamoeba histolytica* is structurally simple and have fun fixed shape. *Entamoeba histolytica* elicit a local secondary immune response with rising of specific secretary IgA (sIgA) that are in several compartments associated to mucosa (3). Numerous inflammatory cells passed through flattened or damaged epithelium into the colonic lumen. Polymorph nuclear leucocytes, neutrophils, eosinophils, and lymphocytes were digested by *amoebae*, as in the well-known ingestion of red blood cells. The NBT consist from two tetrazole molecules consider as the oxidative substance (positive result known from production blue color (4). The redox color nitro blue tetrazolium (NBT) was observed by disconnected neutrophils, that decrease by phagocytosis and that neutrophils from patients. As what happened with incessant chronic granulomatous disease of childhood (CGDC) reduced the dye at an abnormally slow rate in the presence or absence of a phagocytic stimulus. The quantitative NBT test under standard conditions the leucocyte readiness is brooded together with NBT and declining of the color quantitated after extraction into pyridine as figure (1) is exceptionally valuable in the analysis by spectrophotometry (5).

Study sites and water sources in area

The Wassit province is located at the east of country, on the boundary with Iran. The border crossing in area of the study joins the two republics area of the study shares interior margins with the provinces of Diyala, Baghdad, Babil, Qadissiya, Thi-Qar and Missan. Wassit is intersected by the Tigris River, along which a ribbon of irrigated farmland runs, giving way to a dry desert landscape to the north east. Wassit has a dry, desert climate, with temperatures easily exceeding 40°C in summer. Rainfall is scarce and concentrated in the winter months. Just 70% of Wassit's populace has supportable access to an enhanced of improve source water, the lowest percent of all of Iraq. Under 83% of the family units are associated with general water network, and from these less than one fourth has water accessible throughout the day (6).

Others depend on streams, waterways, wells or filtered water and water tankers to satisfy their water needs. The entrance to water changes significantly between the governorate's areas, with as much as 97% of family units in the region of Badra depending on filtered water. The level of individuals with access to an enhanced sanitation office (92%) is marginally lower than the national normal. The circumstance in regards to squander water transfer is unhealthier the condition concerning to waste water disposal is worse only 11,4% of the population relies on the public sewer network, with the rest using septic chambers or a shielded canal. (6)

Materials and methods

Clinical studies

Subjects

This study was performed on 80 male they were divided to 25 control subjects and 55 subjects were diagnosed to be infected by *Entamoeba histolytica* at urban and rural areas in wassit province, their ages range 12 to 27 years old.

This study was performed during the period between September 2016 to July 2017; The control group were 25 apparently healthy male, they were free from signs and symptoms of other disease such as, diabetes mellitus, hypertension, allergic conditions and immunity problems. An information sheets were prepared and designed according to a questionnaire before collection of the samples.

All the patients were diagnosis and collected from AL-zahara teaching hospital and AL -Karma teaching hospital and primary health centers of Badra, Shiegh Saad, AL-Batar and Gehad.

For microscopy each stool sample should be divided into two portions. Direct microscopy should be done by mixing a small amount of the specimen in 0.9% sodium chloride solution (wet amount).

It allows the detection of motile trophozoites of *Entamoeba histolytica* and may also provide information on the contents of the stool, that is, the presence of leucocytes and red blood cells. The second portion of the stool sample was then stained with Lugol's iodine solution to identify trophozoites and cysts. Trophozoites containing ingested RBCs were more common with *E. histolytica* than cyst (7).

Blood Sampling

Five ml of venous Whole sample was withdrawn from each male blood via 5mL syringes. One ml of blood was for NBT stain to determine phagocytic activity. The other three ml of blood was placed in plain tubes and kept at room temperature for clotting, then the serum was separated by

centrifuge at 3000 (RPM) for about 10 minutes.

Nitro-blue tetrazolium dye

This is available commercially, and is made up as a 0.2 % solution in saline. It may require gentle heating to dissolve fully. This solution is stable at room temperature for several weeks. Discard if turbidity or discoloration appears.

Phosphate-buffered saline, pH 7.2

Plastic haemagglutination tray

Pipettes to deliver 0-1 ml

Slides and coverslips Methanol

Pappenheim's stain (methyl green-pyronine) is prepared from the powder supplied commercially. Once made up, the stain is stable for months, but will tend to intensify with time.

Method

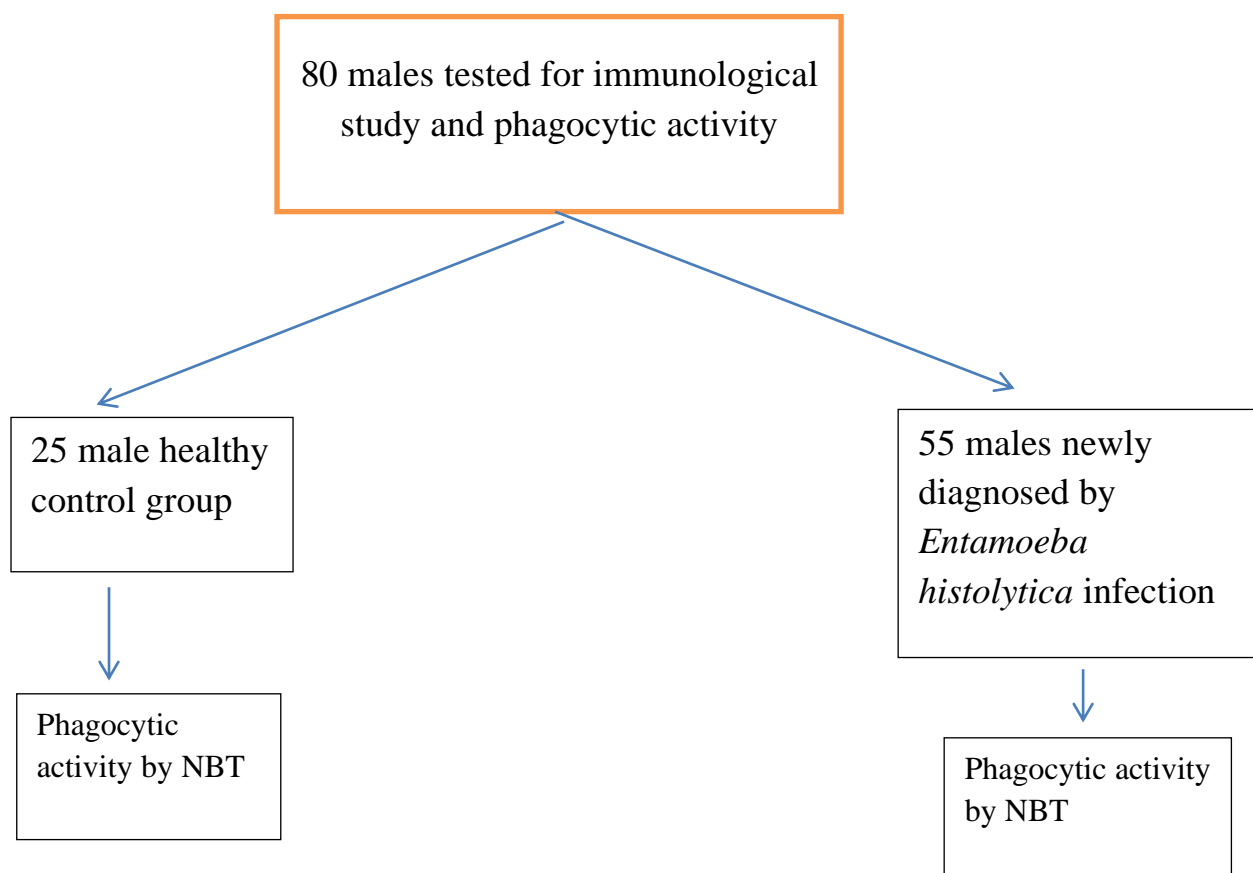
Blood is obtained in glass tubes, using heparin as anticoagulant (the concentration of heparin should be 75-100 units/ml of blood). The usual amounts of blood required from the patient is never more than 10ml. Pipette 0.1 ml of the blood into a well of the plastic tray. Make the 'working' NBT solution by mixing equal volumes of the stock 0.2 % solution and the phosphate-buffered saline. This solution must be made freshly for each batch of tests. Pipette 0.1 ml of the 'working' NBT solution into each well containing blood and mix the contents. Cover the tray with another tray to ensure humidity and incubate at 37°C for 15 minutes. Follow this with an equal period at room temperature.

Using a Pasteur pipette, or a large bacteriological loop, with which to transfer the blood-NBT mixture, make careful coverslip smears and allow them to dry in air. Fix the smears in methanol for three minutes. Stain with Pappenheim's stain for three to five minutes. Then examine under the 40-x objective and assess the number of neutrophils containing the formazan deposit as a percentage. (The actual time is best decided by trial, the desired result

being to stain the granulocyte nuclei green ('ghosts') and to leave most of the erythrocytes as

Study design

The design of the control was as shown below diagram



Results

N.B.T

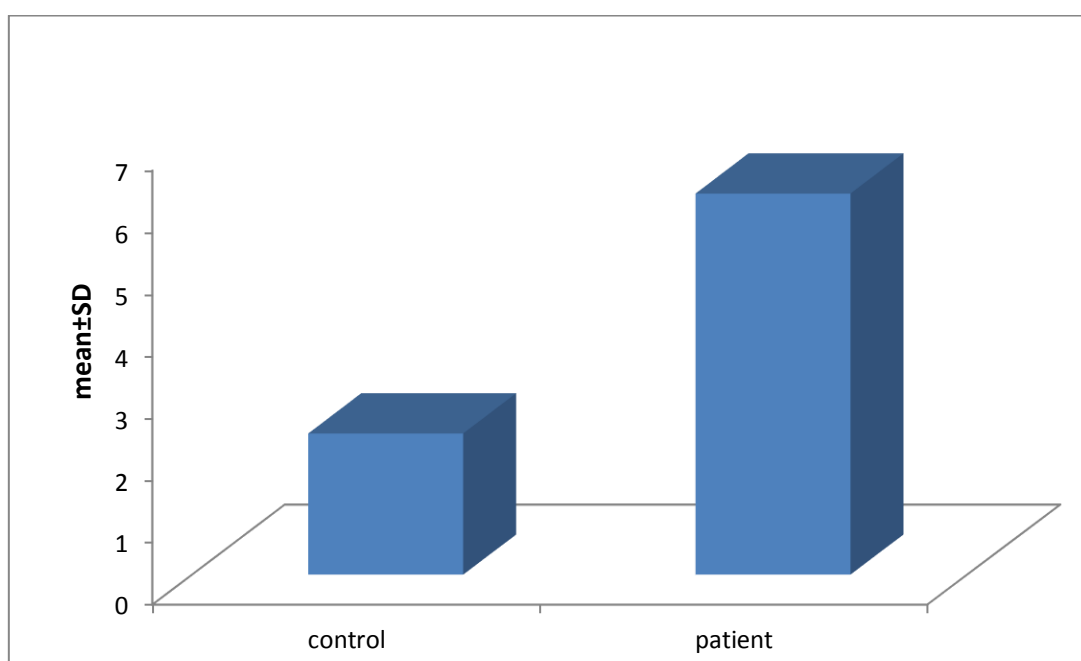
The results showed a significant difference between the two groups (10.96 ± 2.745) for control group and 19.63 ± 3.617 in patients' group with confidence interval (7.056-10.29). P.value $P < 0.001$ ratio minimum

number was 7%, 13% for the control and patient groups. However, the percentage of maximum number in control group was 16% in contrast ,26% for patient group with rang 9%-13% as shown in table (1) figure (1).

Table (1): Mean \pm SD, C.I and *t*-test for N.B.T in patient and control groups

N.B. T	control	Patients	95% Confidence Interval		<i>t</i>	Sig. (2-tailed)
			Lower Bound	Upper Bound		
Valid numbers	25	55	(7.056-10.29)		10.66	<i>P</i> <0.001
Min	7%	13%				
Max	16%	26%				
Range	9%	13%				
Mean \pm SD	10.96 \pm 2.745	19.63 \pm 3.617				

*P:value, SD; Standard deviation; t test

**Figure (1): Bar chart the Mean \pm SD for N.B.T in patients and control group.**

Residency

Patients group

The observation showed that the residency among (22) rural was 60.0% and urban (33) was 40.0% in patients' group, with

confidence interval of (0.186-0.431). Also, there was a noted variation between urban and rural $P \leq 0.05$, although the χ^2 equal (0.309). The N.B.T was variable 13 to 26 in patient group as shown in figure (2).

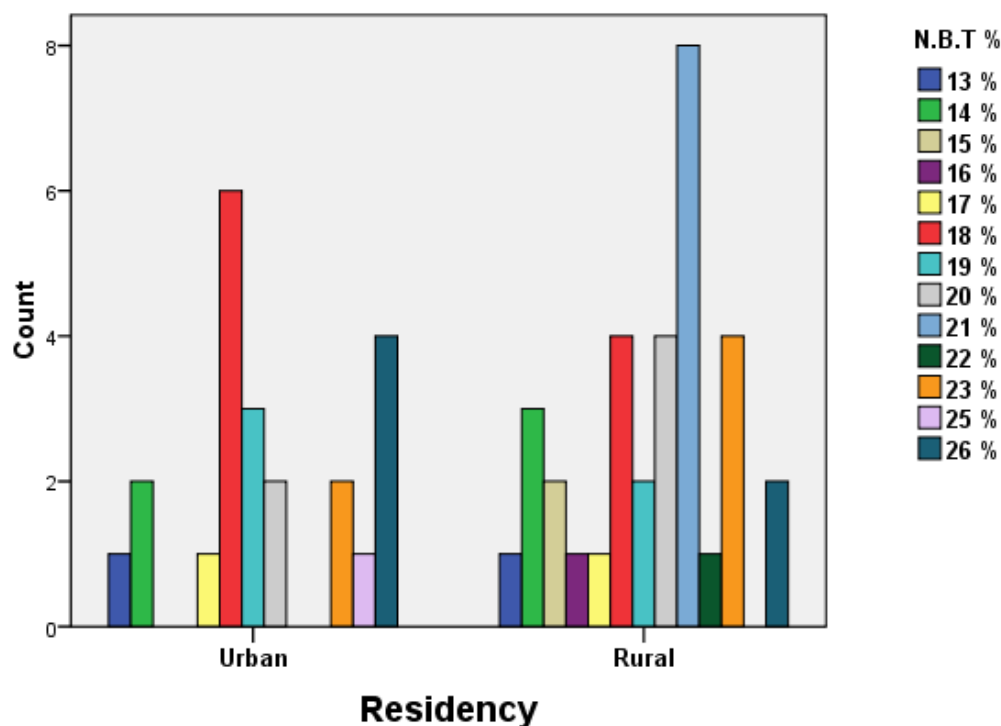


Figure (2): Bar chart for residency of *Entamoeba histolytica* in rural and urban patient groups with N.B.T percentage.

Control group

The observation showed, that the residency among (10) rural was 40.0% and urban (15) was 60.0% for control group while the confidence interval was 0.451- 0.451, in

addition there was signification between urban and rural groups $P \leq 0.05$ and the X^2 equal (0.64). The N.B.T was variable 7 to 16 in control groups as shown in figure (3).

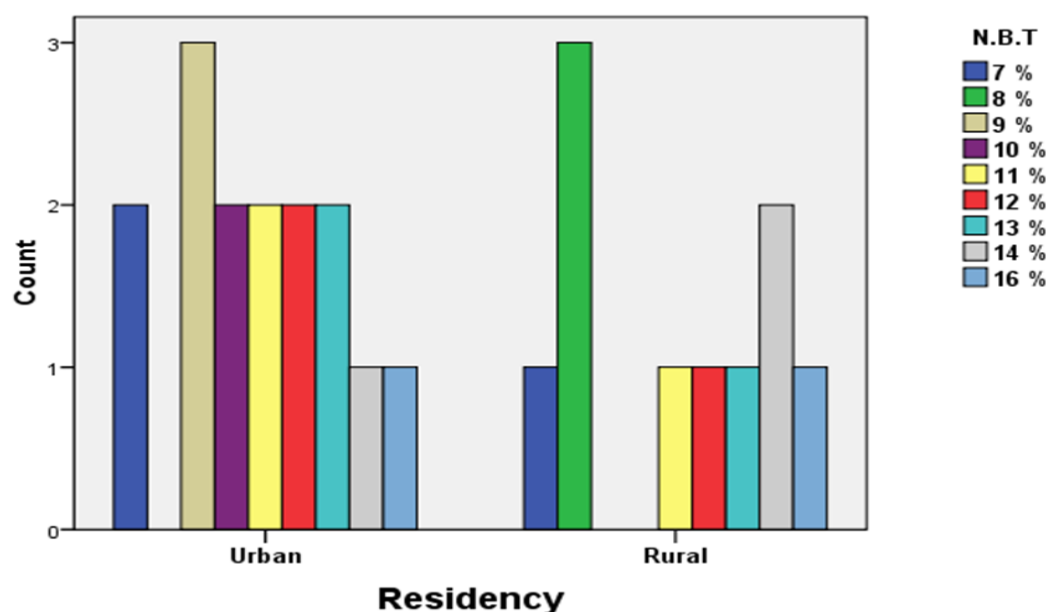


Figure (3): Bar chart for residency of *Entamoeba histolytica* in rural and urban control group with N.B.T percentage.

Discussion

According to our knowledge this is the first study in Iraq, which is done on protozoan parasitic among male newly diagnosed with *Entamoeba histolytica* comparison to healthy male as control group by using distinct immune markers and NBT stain as guide to draw a clear panorama of cellular immunity and phagocytic activity toward the *Entamoeba histolytica*.

Patients infected with *Entamoeba histolytica* showed a wide range of conditions. Some patients showed mild diarrhea with abdominal cramps, eventually resulting fulminant colitis. Because of the tissue damage, that can occur perforation of the intestine and the amoeba may disseminate to other parts of the body. This organism exists either as a trophozoite or a cyst form. Their cyst is stable; once it enters the intestine, it begins to divide into trophozoite, which it binds to the intestinal mucosa via galactose binding lectin on the surface of the organism. This lectin is referred to as the galactose adhesion. Once the trophozoite has attached, it releases tissue damaging enzymes and proteins that lyses the mucosal cell. Amoebic dysentery is a disease that is likely to be underestimated because of a lack of reliable diagnostic laboratory test (8). One of the important things to achieve the whole immunological panorama was using NBT stain and the purpose to study the phagocytic activity by using NTB (nitro blue tetrazolium) stain through measurement the WBCs (white blood cells) and find the active neutrophils and account them the net result calculated as percentage (%). In healthy (control group) the percentages of NBT positive neutrophils (with formazane deposits) was reported to vary between 3% to 11% (9,10). An increase in the positive NBT% was reported in the majority of bacterial and parasitic infections (9,10,11) and may reach up to 75% in acute phase of infection and then decline gradually until return to normal values within 4-6 weeks.

Neutrophils have an essential role in the non-specific (innate) immunity of the body (12). Its increase means that this kind of immunity is efficient.

The results observed phagocytic activity of neutrophils by using (NBT) stain in both patient group and control. It revealed a significant increase of NBT positive neutrophils count in infected male with *Entamoeba histolytica*, in compare with control group, as in the table (3-2) figure (3-2). The efficiency of neutrophils as phagocytes is measured by nitro-blue tetrazolium (NBT) test (11). The nitro-blue tetrazolium dye is converted by the reduction occurring during phagocytosis to an insoluble blue black formazane deposit (9, 11).

The data obtained from present study basically in agreement with Ismail M et al. results, which showed that significant increase in phagocytic activity of polymorph neutrophils (PMNs) for reduction of NBT stain (13).

In conclusion, there were a significant increase in phagocytic activity of polymorph neutrophils (PMNs) for reduction of NBT stain

Reference

- 1- Fotadar, R.; Stark, D.; Beebe, N.; Marriott, D.; Ellis, J.; & Harkness, J.; Laboratory Diagnostic Techniques for *Entamoeba* Species. Clinical Microbiology Reviews. 2007; vol 20 (3): Pp511–515.
- 2- Bruchhaus, I.; Loftus, B.J.; Hall, N.; & Tannich, E.; The intestinal protozoan parasite *Entamoeba histolytica* contains 20 cysteine protease genes. Eukaryot Cell. 2003; vol 2(3): Pp501-9.
- 3- Penuliar, G.M.; Nakada, T. K.; & Nozaki, T.; Phenotypic and transcriptional profiling in *Entamoeba histolytica* reveal costs to fitness and adaptive responses associated with metronidazole

- resistance. *Frontiers in Microbiology*, 2015; vol 6: Pp354.
- 4- Blessmann, J.; Van Linh, P.; Nu, P A.; Thi, H D.; et al. Epidemiology of amebiasis in a region of high incidence of amebic liver abscess in central Vietnam. *Am. J. Trop. Med. Hyg.* 2002; vol 66: Pp578–583.
- 5- Zhang, J. M.; & An, J.; Cytokines Inflammation and Pain. *International Anesthesiology Clinics*. 2007; vol 45(2): Pp 27–37.
- 6- Essa, A.F.; Crisis of Floods and Mines IRAQ (presentation at the 56th session of Committee on the Peaceful Uses of Outer Space) UN Office for the Coordination of Humanitarian Affairs. *Iraq - Floods: Flash Update* .2018; vol 1, Pp 25.
- 7- Haque, R.; Neville, L.M.; Hahn, P.; & Petri, W. A.; “Rapid diagnosis of infection by using Entamoeba and E. histolytica stool antigen detection kits. *J. Cl. Mic*, 1995; vol 33(10): Pp2558–2561.
- 8- Hakan, U.; Osman, A.; & Muhammet, H. U.; Comparison of Various Methods in the Diagnosis of Entamoeba histolytica in Stool and Serum Specimens. *Eurasian J Med*. 2016; vol 48(2): Pp 124–129
- 9- Ahmed, A. A.; Neutrophils phagocytic function in chronic myelogenous leukemia after imatinibmesylate therapy. *Iraqi Journal of Cancer and Medical Genetics*. 2013; vol 6(1): Pp 65-71
- 10- Gupta, RC.; Steigewald, C.; Nitro blue tetrazolium test in the diagnosis of pyogenic arthritis. *Ann.Int.Med*. 1974; vol 80(6): Pp723-726.
- 11- Al-Dabbag, K.A.; & AL-Dabbag, N. Y.; Estimation of total Ig E blood eosinophils and phagocytic activity in human scabies. *ann.coll.med.Mousl*. 2006; vol 32(1&2): Pp 33-40
- 12- Roitt, I.; Brostoff, J.; & Male, D.; Immunology. 6th ed. New York, Mosby. 2001; vol 2: Pp 310.
- 13- Ismail, M.; Daoud, I.; & Hussein, A.; Study of immunological and epidemiological of Toxoplasmosis in aborted women in fallujah city. *Tikrit Journal of Pure Science*. 2013; vol 18 (2): Pp 34-42.