

mRNA *in situ* Hybridization Analysis of Vascular Endothelial Growth Factor and Matrix Metalloproteinase-1 in Colorectal Cancer

Noor Hashim Ismail

Department of Cancer Research, Iraqi Center for Cancer and Medical Genetics Research,
Al-Mustansiriyah University, Baghdad, Iraq.

E-mail: noor.hashim@iccmgr.org

Abstract:

Colorectal cancer is a major global health problem. The aim of the current study is to determine the expression of vascular endothelial growth factor (VEGF) and matrix metalloproteinase -1 (MMP-1), in colorectal cancer patients using *in situ* hybridization technique, formalin-fixed and paraffin embedded tissue sections.

Thirty colorectal cancer patients were obtained from the archive of the pathology laboratory of Al-Yarmouk Teaching Hospital from January 2013 to July 2014. In addition to, formalin-fixed, paraffin embedded tissue sections of twenty normal colon tissues were collected and used as a control group. Each tissue block was subjected to cut as serial thin sections of (4µm) thickness and then fixed on positive charged slides, to be used for *In situ* hybridization for the evaluation of MMP-1 and VEGF expression.

A highly significant difference ($p<0.01$) was noted in the mean percentage of MMP-1 and VEGF mRNA *in situ* expression respectively between the colorectal cancer group and control group. The study revealed a highly significant positive correlation ($P<0.01$) between MMP-1 and VEGF expression in colorectal cancer group. In conclusion, abnormal high expressions of VEGF and MMP-1 may represent the early molecular changes in the development of colorectal cancer.

Key words: Colorectal cancer, *in situ* hybridization, vascular endothelial growth factor, matrix metalloproteinase -1.

تحليل التهجين الموضعي للRNA الرسول لعامل النمو البطاني الوعائي وماتريكس ميتالوبروتينيز-1 في سرطان القولون المستقيمي

نور هاشم إسماعيل

فرع أبحاث السرطان، المركز العراقي لأبحاث السرطان والوراثة الطبية، الجامعة المستنصرية

الخلاصة:

سرطان القولون المستقيمي إحدى المشكلات الصحية الرئيسية عالمياً. الهدف من الدراسة الحالية هو تحديد التعبير عن عامل النمو البطاني الوعائي وماتريكس ميتالوبروتينيز-1 في مرضى سرطان القولون المستقيمي باستخدام تقنية التهجين الموضعي، المقاطع النسيجية المثبتة بالفورمالين ومطمورة بالبرافين.

تم الحصول على ثلاثين خزعة سرطان قولون مستقيمي مثبتة بالفورمالين ومطمورة بالبرافين من أرشيف مختبر الأمراض في مستشفى اليرموك التعليمي للفترة من كانون الثاني 2013 الى تموز 2014، فضلاً عن عشرون عينة مثبتة بالفورمالين ومطمورة بالبرافين من أنسجة القولون الطبيعية تم الحصول عليها وإستخدامها كمجموعة سيطرة. حضرت مقاطع

نسيجية بسمك (4µm) على شرائح زجاجية موجبة الشحنة لكل نسيج لتستخدم في التهجين الموضعي لتقييم التعبير عن عامل النمو البطاني الوعائي وماتريكس ميتالوبروتينيز-1.

لوحظ وجود فرق معنوي في متوسط النسبة المئوية لتعبير عامل النمو البطاني الوعائي وماتريكس ميتالوبروتينيز-1 على التوالي بين مجموعة سرطان القولون المستقيمي ومجموعة السيطرة. كشفت الدراسة عن ارتباط ايجابي كبير للغاية ($P < 0.01$) بين تعبير عامل النمو البطاني الوعائي وماتريكس ميتالوبروتينيز-1 في مجموعة سرطان القولون المستقيمي. وجد أن التعبير العالي غير الطبيعي لعامل النمو البطاني الوعائي، و ماتريكس ميتالوبروتينيز-1 قد يمثل أحد التغيرات الجزيئية المبكرة في تطور سرطان القولون المستقيمي.

الكلمات المفتاحية: سرطان القولون المستقيمي، عامل النمو البطاني الوعائي، ماتريكس ميتالوبروتينيز-1.

Introduction:

Worldwide, colorectal cancer is the second most common cancer in women and the third in men^[1,2]. In Iraq, according to the 2012 Iraqi Cancer board report, colorectal cancer ranked the sixth among the commonest ten leading cancers in 2010^[3].

Vascular endothelial growth factor (VEGF) is an endothelial, cell-specific mitogen. It has been characterized as a major regulator of angiogenesis with many physiological and pathological, during development and adulthood^[4,5]. Angiogenesis is a multi-step process, it involves the sprouting of new blood vessels from pre-existing vasculature; it is an essential for the growth and progression of solid tumors^[6]. Vascular endothelial growth factor (VEGF) is a positive regulator of angiogenesis; it plays a key role in tumor angiogenesis and shows a high expression in many tumors including colorectal cancer^[7].

Tumor invasive nature is associated with degradation of the interstitial stroma, which is the main component of the extracellular matrix (ECM)^[8]. Matrix metalloproteinases (MMPs) family is an extracellular matrix proteolytic enzyme, which is selectively degrading various proteins of ECM. This event can be supported by collagenases, particularly interstitial collagenase matrix metalloproteinase -1 (MMP-1)^[9]. MMP-1 specifically degrades collagens I, II, and III^[10].

The objective of the current study is to determine the expression of VEGF and MMP1 and the correlation of their expression in colorectal cancer.

Materials and Methods:

Tissue samples, sectioning and slide preparation

This study was designed as a retrospective study. Thirty Formalin-fixed, paraffin embedded tissue sections from colorectal cancer patients were obtained from the archive of the Pathology laboratory of Al-Yarmouk Teaching Hospital from January 2013 to July 2014. The diagnosis of these tissue sections were primarily based on their accompanied records. In addition Formalin-fixed, paraffin embedded blocks from twenty normal colon tissues were collected and used as control group. All tissue sections were subjected to cut as serial thin sections of (4µm) thickness and were fixed on positive charge slides to be used for *In situ* hybridization for the evaluation of MMP-1 and VEGF expression. Ethical approval for use of all specimens was obtained.

In situ hybridization procedure (ISH)

In situ hybridization was conducted in accordance with manufacturer's instruction (Maxim Biotech, Inc., USA) in histopathology laboratory, cancer research department at Iraqi center for cancer and medical genetic

research, Al-Mustansiriyah University. For *in situ* hybridization technique, DNA Probe Hybridization/Detection System *in situ* kit (Maxim Biotech, Inc., USA, cat # IH-60001(IH-0050), high sensitivity type) was used. The probes were biotinylated long DNA probes for Human MMP-1 (395bp.) (Maxim Biotech, Inc., USA, cat # IH-60024) and VEGF, all types (294bp.) (Maxim Biotech, Inc., USA, cat # IH-60038).

Briefly, slides were heated at 60°C in oven overnight, deparaffinized in xylene and graded alcohols. The tissue was digested with 1X proteinase k solution for 15 min at 37 °C. The tissue slides were washed in deionised water dehydrated in graded alcohols, and dried by incubation at 37°C for 5 minutes. After application of a denatured biotinylated probes for MMP-1 and VEGF to the target sequence and denaturation of the target mRNAs in tissue sections, hybridization conducted by overnight incubation at 37°C using moisturised chamber. Post-hybridization wash was performed the next day, followed by detection using the DNA Probe hybridization, detection System *in situ* kit. Hybridization, detection System yields an intense blue- black signal that appears at the specific site of the hybridized probe.

Scoring

The mRNA of MMP-1 and VEGF were measured by counting the positive cells in the tissue that appear with a blue-black (BCIP/NBT) nuclear staining under the light microscope. The score was the average from 10 distinct high-power fields observed under ×400 magnification. The percentage of positively stained cell was calculated for each case by taking the mean of the percentages of the positively stained cell in the 10 fields. MMP-1 and VEGF mRNA expression was classified into four categories, depending on the percentage of cells stained: 0 = no staining, 1 = positive

Date of acceptance: 25-7-2016

staining in <25% of the sample, 2 = positive staining in 25%–50% of the sample, 3 = positive staining in >50% of the sample. ^[11].

Statistical analysis

Statistical analysis was done using Student test (t-test), Chi-Square test (χ^2), and Pearson Correlation (r) to determine the difference in the *in situ* expression of MMP-1 and VEGF between different groups (colorectal cancer and control group). All statistical analysis was conducted using Statistical Package for Social Sciences (SPSS) version 22. Values were considered statistically significant when $p < 0.05$, $p < 0.01$ and non-Significant.

Results:

***In situ* hybridization detection of MMP-1 and VEGF**

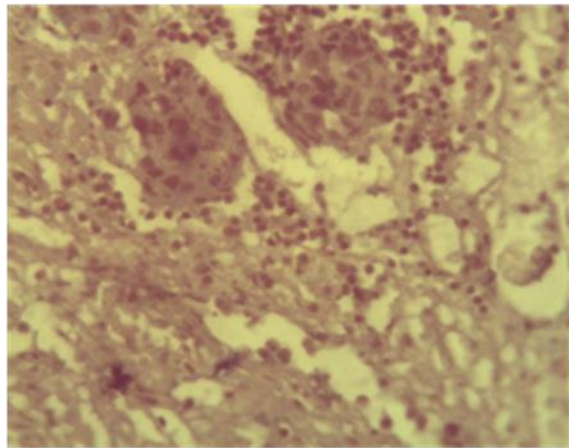
The results of *in situ* hybridization detection of MMP-1 and VEGF, as shown in (tables-1and 2, figures-1 and 2), and based on t-test of significant, there were highly significant difference ($p < 0.01$) in the mean percentage of MMP-1 and VEGF mRNA *in situ* expression respectively in the colorectal cancer group compared with control group.

Table-1: The expression of MMP-1 mRNA ISH % in study group.

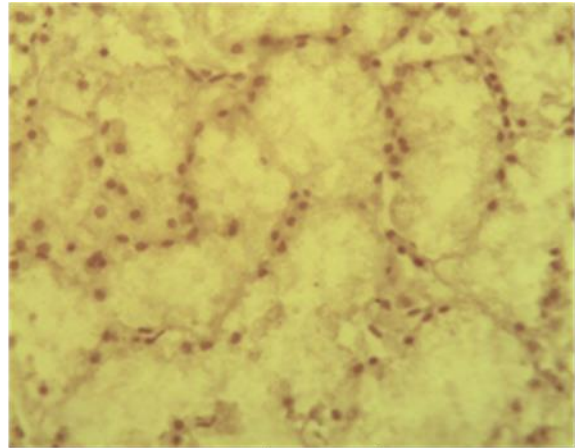
Group	No.	Expression of MMP-1 mRNA ISH % (Mean ±S.E.)	Comparison of Significance	
			p-value	significance
Colorectal cancer	30	67.05±4.65	0.000	Highly significant (p<0.01)
Control	20	6.21±1.89		

Table-2: The expression of VEGF mRNA ISH % in study group.

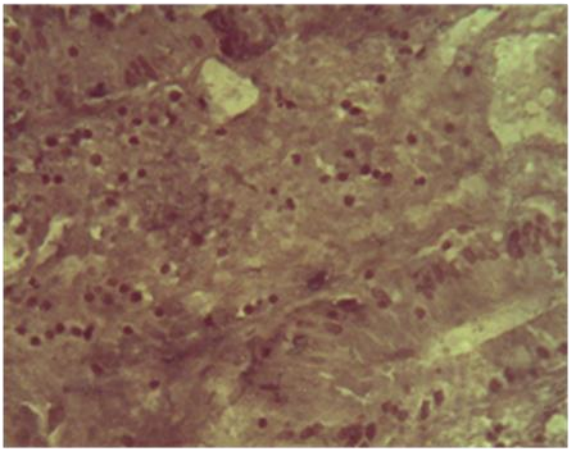
Group	No.	Expression of VEGF mRNA ISH % (Mean ±S.E.)	Comparison of Significance	
			p-value	significance
Colorectal cancer	30	61.81±4.62	0.000	Highly significant (p<0.01)
Control	20	5.15±1.87		



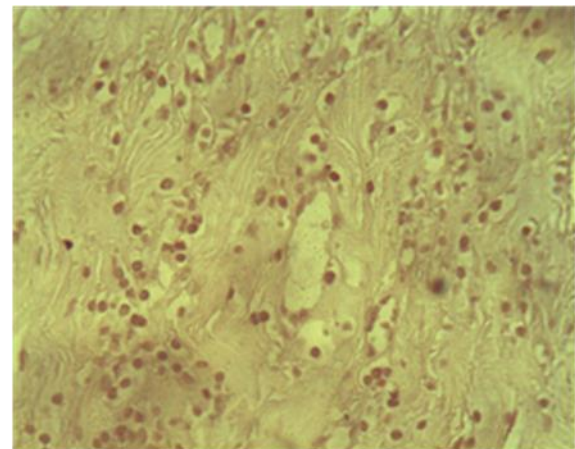
A



B



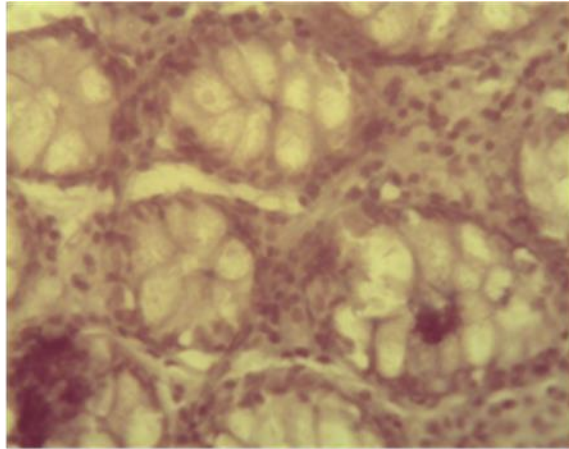
C



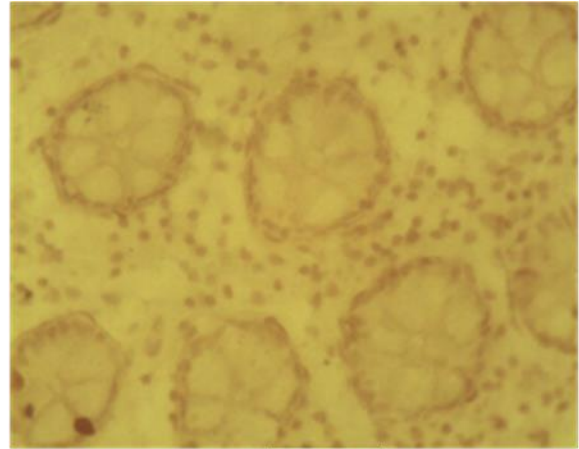
D

Figure-1: *In situ* hybridization for MMP-1 and VEGF of colorectal cancer using BCIP/NBT substrate/chromogen and counter stained by Hematoxyline (X400).

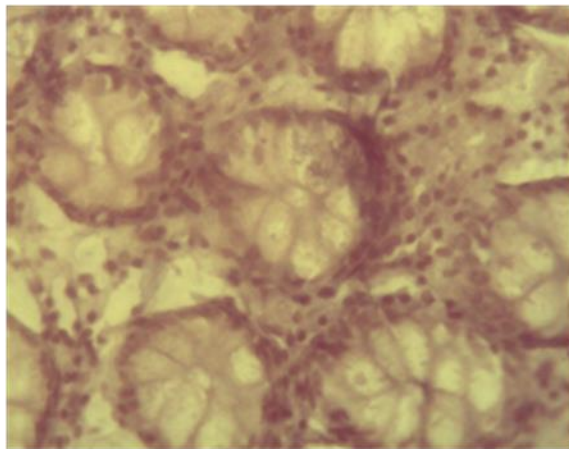
- A- Positive expression of MMP-1.
- B- Negative expression of MMP-1.
- C- Positive expression of VEGF.
- D- Negative expression of VEGF.



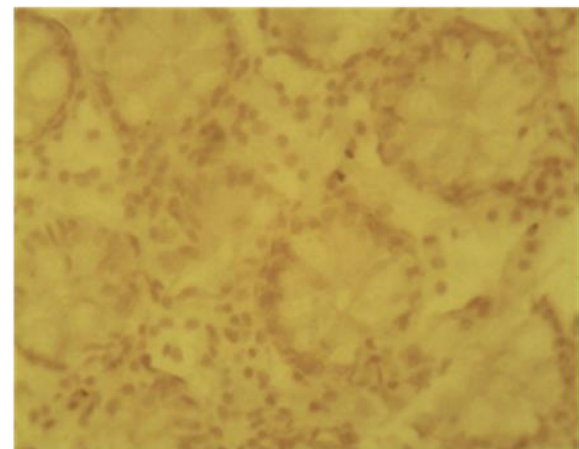
A



B



C



D

Figure-2: *In situ* hybridization for MMP-1 and VEGF of normal colon using BCIP/NBT substrate/chromogen and counter stained by Hematoxyline (X400).

- A- Positive expression of MMP-1.
- B- Negative expression of MMP-1.
- C- Positive expression of VEGF.
- D- Negative expression of VEGF.

Statistical analysis using Chi-square test to study the association between MMP-1 and VEGF mRNA expression. Results revealed a highly significant association ($p < 0.01$) between the colorectal cancer group and control group in the four scoring levels (table-3 and 4). High percentage of MMP-1 expression was detected in 80% (24 out of 30) of colorectal cancer patients tissues in high score (score 3) while in control group 60% (12 out of 20) were detected in low score (score 0). VEGF

expression high percentage was found in 76.7% (23 out of 30) of colorectal cancer patients tissues in high score (score 3) while in control group 70% (14 out of 20) were detected in low score (score 0). Furthermore, the study showed a highly significant positive correlation ($P < 0.01$) between MMP-1 and VEGF expression in colorectal cancer group and a significant positive correlation ($P < 0.05$) between MMP-1 and VEGF expression in control group (table-5).

Table-3: Frequency distribution of ISH for MMP-1 according to signal percentage score among study group.

Group	No.	MMP-1 score N (%)				Comparison of significance	
		0	1	2	3	p-value	significance
Colorectal cancer	30	1(3.3%)	3(10%)	2(6.7%)	24(80%)	0.000	Highly significant ($p < 0.01$)
control	20	12(60%)	8(40%)	0(0%)	0(0%)		

Table-4: Frequency distribution of ISH for VEGF according to signal percentage score among study group.

Group	No.	VEGF				Comparison of significance	
		0	1	2	3	p-value	significance
Colorectal cancer	30	1(3.3%)	2(6.7%)	4(13.3%)	23(76.7%)	0.000	Highly significant ($p < 0.01$)
control	20	14(70%)	6(30%)	0(0%)	0(0%)		

Table-5: Correlation of MMP-1 and VEGF mRNA expression in study group.

Variable	Group	Correlation Coefficient (r)	p-value	Significance
MMP-1 and VEGF	Colorectal cancer	0.621	0.000	Highly significant ($p < 0.01$)
	Control	0.437	0.035	Significant ($p < 0.05$)

Discussion:

This study described the expression of VEGF and MMP-1 mRNA respectively in the colorectal cancer patients and control group (normal colon) tissues. Using *in situ* hybridization, the results of the present study showed that, a highly significant difference ($p < 0.01$) in the mean percentage of MMP-1 mRNA *in situ* expression in the colorectal

cancer group compared with the control group. MMP-1 mRNA high percentage, was detected in 80% (24 out of 30) of colorectal cancer patients tissues in high score (score 3) while in control group 60% (12 out of 20) were detected in low score (score 0). The major proteins in the extracellular matrix in the gastrointestinal tract are collagens, especially of types I and III, which are

important for cell adhesion and the invasion of carcinoma cells^[13]. MMP-1, belong to the family of MMPs and specifically degrades collagens I, II, and III. In addition, it can cleave several other matrix and non-matrix proteins including growth factors, and this way regulate cell growth and survival^[14]. These results are consistent with result of previous studies that reported increased expression of MMP-1 mRNA in the colorectal cancer patients tissues compared with normal control^[15, 16, 17].

The resultsof this study also revealed a high significant difference ($p < 0.01$) in the mean percentage of VEGF mRNA *in situ* expression in the colorectal cancer group compared with control group. Based on scoring level VEGF mRNA higher percentage was detected in 76.7 % (23 out of 30) of colorectal cancer patients in high score (score 3) while in control group 70% (14 out of 20) were detected in low score (score 0).

Angiogenesis is an important process in tumor growth, invasion and metastasis^[18,19]. VEGF is one of the angiogenic factors, that regulate the angiogenesis process^[20]. These findings possibly manifest the important role of VEGF cellular expression in the pathogenesis of colorectal cancer and reflect degree of vascularization of colorectal cancers as detected by *in situ* hybridization and immunohistochemistry^[21, 22, 23, 24].

Furthermore, the study revealed a highly significant positive correlation ($P < 0.01$) between MMP-1 and VEGF expression in colorectal cancer group and a significant positive correlation ($P < 0.05$) between MMP-1 and VEGF expression in control group. These results showed that , MMP-1 and VEGF are highly interact with each other and function synergistically, subsequently increasing their effect in colorectal cancer, in line with their contribution to development of a tumor vasculature allowing malignant tumors growth and metastatic spread^[20]. Angiogenesis is

Date of acceptance: 25-7-2016

dependent, at least in part, on the functions of MMPs, since they involved in degradation of the basement membrane and perivascular ECM components, release of angiogenic factors, production of endogenous angiogenic inhibitors, and the unmasking of cryptic biologically relevant sites in ECM components^[25].

Conclusions:

In conclusion, VEGF, and MMP- 1 play an important role in colorectal carcinoma. Abnormal expressions of VEGF and MMP-1 may represent one of the early molecular changes in the development of colorectal cancer.

References:

- 1 - Jemal A, Center MM, DeSantis C, Ward EM. Cancer Epidemiol Biomarkers Prev. 2010 ; 19(8): 1893-907.
- 2 - Jemal A, Bray F, Center MM, Ferlay J, Ward E, Forman D. Global Cancer Statistics. Cancer J Clin. 2011; 61(2): 69–90.
- 3 - Ministry of Health, Iraqi Cancer Board (2012). Results of Iraqi Cancer Registry. 2010.
- 4 - Ferrara N. VEGF and the quest for tumor angiogenesis factors. Nat Rev Cancer. 2002; 2(1): 795-803.
- 5 - Hoeben A, Landuyt B, Highley MS, Wildiers H, Van Oosterom AT, De Bruijn EA. Vascular Endothelial Growth Factor and Angiogenesis. Pharmacol Rev. 2004; 56(4): 549–58.
- 6 - Pang RWC, Poon RTP. Clinical implications of angiogenesis in cancers. Vascular Health and Risk Management . 2006; 2(2): 97–108.
- 7 - Welti J, Loges S, Dimmeler S, Carmeliet P. Recent molecular discoveries in angiogenesis and antiangiogenic therapies in cancer. The Journal of Clinical Investigation. 2013; 123(8): 3190-200.

- 8 - Herszényi L, Hritz I, Lakatos G, Varga MZ, Tulassay Z. The Behavior of Matrix Metalloproteinases and Their Inhibitors in Colorectal Cancer. *Int. J. Mol. Sci.* 2012; 13(1): 13240-63.
- 9 - Itoh Y, Nagase H. Matrix metalloproteinases in cancer. *Essays Biochem.* 2012; 38: 21-36.
- 10 - Visse R, Nagase H. Matrix metalloproteinases and tissue inhibitors of metalloproteinases: structure, function, and biochemistry. *Circ Res.* 2003; 92(8): 827-39.
- 11 - Zhigang Z, Wenlv S. Prostate stem cell antigen (PSCA) expression in human prostate cancer tissues and its potential role in prostate carcinogenesis and progression of prostate cancer. *World Journal of Surgical Oncology.* 2004; 2: 13.
- 12 - Sorlie DE. Medical biostatistics & epidemiology: Examination & board review. 1st ed. Norwalk, Connecticut, Appleton & Lange, 1995; 47-88.
- 13 - Bode MK, Karttunen TJ, Mäkelä J, Risteli L, Risteli J. Type I and III collagens in human colon cancer and diverticulosis. *Scand J Gastroenterol.* 2000; 35(7): 747-52.
- 14 - Ala-aho R, Kähäri VM. Collagenases in cancer. *Biochimie.* 2005; 87(3-4): 273-86.
- 15 - Shiozawa J, Ito M, Nakayama T, Nakashima M, Kohno S, Sekine I. Expression of Matrix Metalloproteinase-1 in Human Colorectal Carcinoma. *Mod Pathol.* 2000; 13(9): 925-33.
- 16 - Gray ST, Yun K, Motoori T, Kuys YM. Interstitial Collagenase Gene Expression in Colonic Neoplasia. *Am J Pathol.* 1993; 143(3): 663-71.
- 17 - Kitadai Y, Ellis LM, Takahashi Y, Bucana CD, Anzai H, Tahara E, *et al.*. Multiparametric *in Situ* Messenger RNA Hybridization Analysis to Detect Metastasis-related Genes in Surgical Specimens of Human Colon Carcinomas. *Clinical Cancer Research.* 1995; 1(10): 1095-102.
- 18 - Nishida N, Yano H, Nishida T, Kamura T, Kojiro M. Angiogenesis in cancer. *Vascular Health and Risk Management.* 2006; 2(3): 213-19.
- 19 - Rmali KA, Puntis MCA, Jiang WG. Tumour-associated angiogenesis in human colorectal cancer. *Colorectal Disease.* 2006; 9(1): 3-14.
- 20 - Mousa L, Salem ME, Mikhail S. Biomarkers of Angiogenesis in Colorectal Cancer. *Biomarkers in Cancer.* 2015; 7(S1): 13-19.
- 21 - Mustafa IAM, AL-Khurri LE. VEGF in situ mRNA expression along with different histopathological parameters of colorectal adenocarcinoma. *Al-Qadisiyah Medical Journal.* 2010; 6: 38-51.
- 22 - Jubb AM, Hurwitz HI, Bai W, Holmgren EB, Tobin P, Guerrero AS, *et al.*. Impact of Vascular Endothelial Growth Factor-A Expression, Thrombospondin-2 Expression, and Microvessel Density on the Treatment Effect of Bevacizumab in Metastatic Colorectal Cancer. *J Clin Oncol.* 2006; 24(2): 217-27.
- 23 - Hashim AF, Al-Janabi AA, Mahdi LH, Al-Toriahi KM, Yasseen AA. Vascular endothelial growth factor (VEGF) receptor expression correlates with histologic grade and stage of colorectal cancer. *Libyan J Med.* 2010; 5: 5059.
- 24 - Gomes EG, Jucá MJ, de Menezes HL, Nunes BL, Costa H, Lima Fde O, *et al.*. Correlation between the immunohistochemical expressions of MMP-1, MMP-7 and VEGF and prognostic factors in colorectal adenocarcinoma. *Acta Cir Bras.* 2009; 24(4): 303-10.
- 25 - Lafleur MA, Handsley MM, Edwards DR. Metalloproteinases and their inhibitors in angiogenesis. *Exp Rev Mol Med.* 2003; 5(23): 22.