

## Traumatic Diaphragmatic Rupture

Sameer Mohi-Aldeen

College of Medicine, Al-nahrain University Baghdad-Iraq.

E-mail: Samir\_frsc@yahoo.com.

### Abstract:

To describe changes in the presentation, examination of the chest in patients with diaphragmatic rupture, was reviewed to identify the difficulty in the diagnosis and treatment of this injury. Between April 2006-and December 2012, 38-patients with traumatic diaphragmatic rupture were treated, and analyzed demographic data , cause of injury, extent and location of the diaphragmatic lesion with herniated organs, were described the clinical presentation.

Retrospective study of 38-cases, 36-male, 2-female, 37 cases left side, one case right side. Main cause was penetrating injury 35-cases, blast injury (12), gunshot (16), stab (7). Blunt injury 3-cases, road traffic accident (2), post-operative damage and tear the diaphragm (1) case. Average age33-year, range (4-65years old).The diagnosis made by C-XR, C-T Scan, MRI, were grade of injury II-IV most common, associated injury stomach, spleen, bowel, kidney, retroperitoneal hematoma, liver. Repair through laparotomy and thoracotomy. Chest pain abdominal pain shock was the main presentation.

The study showed the suspicion beside the radiological C-XR, C-T Scan are very useful in initial diagnostic approach to traumatic diaphragmatic rupture. The difficulty is that diaphragmatic injuries particularly after penetrating trauma may initially go unnoticed and without changes in the C-XR Images diagnosis is made difficult. Early diagnosed, treatment reduces intra and postoperative morbidity and mortality.

**Key words:** Diaphragmatic rupture, Repair, Radiology, Trauma, Laparotomy, Thoracotomy.

### اصابات الحجاب الحاجز التمزقية

محي الدين سمير احمد محمد

كلية الطب، جامعة النهرين

تهدف هذه الدراسة لمعرفة التغيرات التي تصاحب إصابات تمزق الحجاب الحاجز من أعراض وفحص سريري للبطن والصدر، تم استعراض الصعوبات التي تواجه التشخيص والعلاج المبكر لهذه الاصابات، حيث تم علاج 38 مريضاً مصابين بمزق الحجاب الحاجز نتيجة الاصابات للفترة بين نيسان (ابريل) 2006 وكانون الاول (ديسمبر) 2012، وتحليل البيانات الديموغرافية لمعرفة طرق الاصابات ونوع الاصابة وحجمها ودخول أحشاء البطن الى الصدر ووصف علامات سريرية لهذه الاصابات.

بينت النتائج من خلال دراسة استرجاعية لـ 38 حالة (36 حالة من الذكور، 2-أناث)، منها (37 حالة الجانب الايسر، وحالة واحدة في الجانب الأيمن)، حيث تبين أن السبب الرئيسي هو اصابات الاختراقية 35 حالة، منها اصابات الانفجار (12)، طلق ناري (16)، طعن بأداة حادة (7)، اصابات غير مختزقة (شدة خارجية) 3 حالات، منها إصابة حادث مرور (2)، والضرر ما بعد الجراحة وتمزق الحجاب الحاجز (1) حالة، وكان متوسط العمر 33 سنة، ومعدل العمر (4-65 سنة)، وكان التشخيص عن طريق الأشعة السينية، الأشعة المقطعية، الرنين المغناطيسي، وكانت درجة الإصابة II-IV الأكثر شيوعاً في المعدة، الطحال، الأمعاء والكلية.

أظهرت الدراسة ان التشخيص هو عن طريق اشتباه والشك وكذلك الفحوصات الإشعاعية السينية، الأشعة المقطعية هي مفيدة للوصول للتشخيص الاولي لتمزق الحجاب الحاجز وتكمن الصعوبة في التشخيص للإصابات الحجاب خصوصاً بعد الاصابات الاختراقية قد تذهب دون أن يلاحظها أحد في البداية وقد تحدث دون ظهور العلامات في الرقائق الشعاعية الاولية مما يؤدي الى صعوبة التشخيص. وأكدت الدراسة أن التشخيص المبكر والعلاج المبكر يقلل من نسبة المضاعفات والوفيات.

### Intraoduction:

Diaphragmatic injuries are relatively rare, but are no longer an uncommon entity, and result from blunt trauma or penetrating trauma. Injuries of the diaphragm often challenge to the surgeon by the subtle presentation in the face of more obvious injuries.

The post-traumatic diaphragmatic hernia occurs when one or more abdominal organs or other structures, such as omentum or peritoneal fat, protrude through the injured diaphragm.

Thus, abdominal organs leave their original cavity and invade that of the thorax.

Diaphragmatic injuries were described first by Sennetus 1541<sup>[1]</sup>. Riolfi performed the first successful repair in 1886<sup>[2]</sup>. Not until 1951 when Carter et al published the first case series, was this injury well understand and delineated<sup>[3]</sup>.

Diaphragmatic rupture occur (1-7%) of major blunt trauma victims and in (10-15%) of patient with penetrating trauma<sup>[4]</sup>.

These can divided into penetrating (25%) and non-penetrating ones (75%)<sup>[5]</sup>. Blunt trauma causes large defects, and 10% of pelvic fractures are associated with diaphragmatic rupture. In blunt trauma, sudden increase in intra-abdominal pressure may cause a 'blow out' or tear at the weakest point in the diaphragm, most commonly the left poster lateral diaphragm (over 80%). The stronger right side is 'protected' by large liver. Intra-abdominal contents, commonly colon, stomach, and spleen may herniate into the chest, often not detected in multiply injured and ventilated patients. Difficulty passing a nasogastric tube or the intrathoracic

positioning of a successfully placed nasogastric tube may assist in the diagnosis of the ruptured diaphragm with stomach in the chest.

Diaphragmatic ruptures without herniation are difficult to demonstrate on computerized tomography scan, and the diagnosis is often accidental, such as the appearance of abdominal lavage fluid or gastric content from a perforated stomach in the chest tube container after chest tube insertion, or appearance of a pneumoperitoneum on plain x-ray with coexisting thoracic trauma.

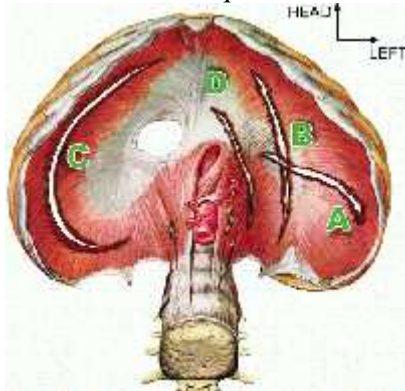
Diaphragmatic defects do not spontaneously close, regardless of the size, because of the pleuroperitoneal pressure gradient caused by respirations. If undetected in the early period, non-specific abdominal complaints due to intermittent herniation of abdominal visceral contents may be the subsequent presenting symptom even well after discharge. Bowel obstruction and incarceration may occur.

Finally, bowel ischemia and subsequent bowel necrosis may result. When such patients are intubated and sedated for other injuries, the possibility of such a missed injury or delay in diagnosis may result in serious life threatening injury to the patient.

Operative closure and relocation of abdominal contents is mandatory. The diaphragm may be approached from either the chest or the abdomen, and recent reports have demonstrated the ability to repair the diaphragm laparoscopically or thoracoscopically in a stable patient.

Organ Injury Scale (Diaphragm) (AATS) American Association for Trauma Surgery, Figure-1.

Grade	Injury Description	AIS-90
I	Contusion	2
II	Laceration < 2 cm	3
III	Laceration 2-10 cm	3
IV	Laceration > 10 cm	3
V	Laceration with tissue loss > 25sqcm	3



**Figure-1: Location of Diaphragmatic injury.**

### Materials and Methods:

The records of 38-patients who presented and treated in our unit of cardiothoracic and vascular surgery in Al-Kadhimia teaching hospital. Those patients presented with blunt and penetrating diaphragmatic injury, whether early or late from April 2006 to December 2012 were reviewed retrospectively. Most of the patients were admitted through emergency department, other patients referred from other departments. Penetrating injuries are more common due to suicidal bombs, blast injury, bullet, stab wound. Blunt injury the main cause was compression trauma, road traffic accident, post-operative complication also reported. Diagnosis was made on chest radiographs (C-XR) initially, in some cases computed tomography (C-T) scans of the upper abdomen and the chest was done to confirm the diagnosis. Magnetic Resonance Image (MRI) done in one case. Nasogastric intubation was done in all cases.

The severity of the injury of the diaphragm was classified according to the injury scale of the American Association for Surgery of Trauma (AAST), Grade I, II, III, IV, V. Other diagnostic methods such as diagnostic peritoneal lavage. Lapa-

rotomy, thoracotomy, or thoracotomy on the left side.

The operative approach was represented by midline laparotomy, other by thoracotomy at the 7<sup>th</sup> intercostal space. Repair was done by non-absorbable sutures (Silk, Nylon, Prolene) double layers one interrupted second layer over swing continuous. One case was done with Teflon patch graft to facilitate reconstruction of diaphragm. Chest intubations were done in all cases. Medical records included age, sex, injury pattern, injury severity, morbidity and mortality and outcome.

### Results:

From April 2006 to December 2012, we evaluated the medical records of the diaphragmatic trauma 38 patients with rupture diaphragm who underwent exploratory laparotomy and thoracotomy. Male 36 cases (94.7%), Female 2 cases (5.2%). Average age 33-years, ranging from 4-65 years. Left side 37-cases (97.4%), while Right side 1-case (2.6%) of the all cases. Penetrating trauma was the most common cause 35-cases (92%).

Blunt trauma 3-cases (8%), Penetrating trauma, blast injuries 12-cases (31.5%), gun-shot 16-cases (47.3%), stab wounds 7-cases (18.4%), Blunt trauma car accident 2-cases (5.2%), and 1-case (2.6%) post-operative. (Table-1) We analyzed demographic data the severity of the injury of the diaphragm according to American Association for Surgery of Trauma (AAST) grade-I zero, grade –II (17-cases 44.7%), grade-III (13-cases 34.2%), grade-IV (7-cases 18.4%), grade-V (1-case 2.6%), (Table-2). Chest X-ray (CXR) were obtained for all patients, computed tomography (C-T scan), magnetic resonance imaging (MRI), Figure-2,3.

Traumatic diaphragmatic rupture may presented with chest pain 10-cases (26.3%), shock due to hypovolemic 12-cases (31.5%), abdominal pain 20-cases (52.6%), dyspnea 5- cases (13.1%), shoulder pain 4- cases (10.2%)/ (Table -3). During exploration we found the organs

affected more seen the stomach 10-cases (26.3%), spleen 8-cases (21.02%), liver 3-cases (7.8%), bowels 8-cases (21.02%), left lung 5-cases (13.1%), left kidney 3-cases (7.8%), retroperitoneal hematomas 1-case (2.6%), (Table-4, Figure-4).

The injuries were repaired primarily with non-absorbable suture (nylon) double layers Figure-5, one case using a Teflon patch graft. Tube thoracostomy inserted in the side of the repaired of the diaphragm. The patients admitted to

the thoracic intensive care unit for 24-hours, chest physiotherapy and breathing exercise to promote lung expansion. Morbidity rate lung atelectasis 4-cases (10.5%), sepsis 5-cases (13.1%), urinary tract infection 2- cases (5.2%), gastrointestinal problem 5- cases (13.1%), (Table-5).

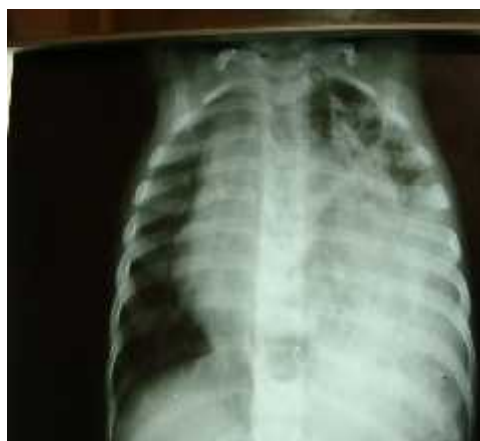Mortality rate 3-cases (7.8%) all are male cause of death are irreversible shock.

**Table-1: Types of Trauma.**

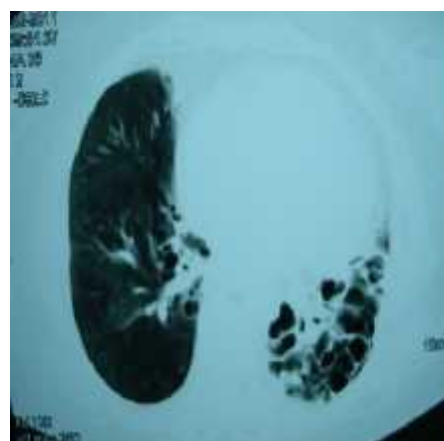
PENETRATING INJURY	BLAST INJURY	12	31.5%
	GUNSHOT	16	47.3%
	STAB WOUND	7	18.4%
BLUNT TRUMA	ROAD TRAFFIC ACCIDENT (RTA)	2	5.2%
POST-OPERATIVE	TRAUMA TO DIAPHRAG POST-LAPAROTOMY	1	2.6%
TOTAL NUMBER	35-PENETRATING,3-BLUNT	38	100%

**Table-2: Stages of Injury according to (AATS).**

STAGE I	0	0%
STAGE II	17	44.7%
STAGE III	13	34.2%
STAGE IV	7	18.4%
STAGE V	1	2.6%



**Figure-2: Chest X-Ray (TDR) Left side**



**Figure-3: Chest C-T Scan (TDR)**

**Table-3: Clinical Symptoms/Presentation.**

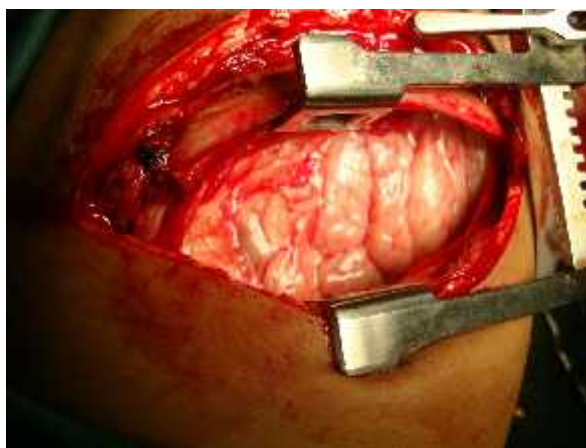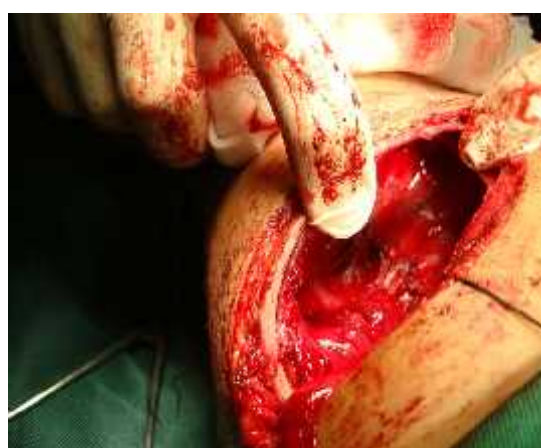Shock	12	31.5%
Abdominal Pain	20	52.6%
Chest Pain	10	26.3%
Dyspnea	5	13.1%
Shoulder Pain	4	10.2%

**Table-4: Organs involved, (Viscera Affected).**

Stomach	10	26.3%
Spleen	8	21.02%
Liver	3	7.8%
Bowel	8	21.02%
Left Lung	5	13.1%
Kidney	3	7.8%
Retroperitoneal Hematoma	1	2.6%

**Table-5: Morbidity.**

Lung Atelectasis	4	10.5%
Sepsis	5	13.1%
Urinary tract infection	2	5.2%
Gastrointestinal problem	5	13.1%

**Figure-4: Organs herniated (Affected Organs)****Figure-5: Operative repair Left Thoracotomy**

## Discussion:

The first report of penetrating traumatic diaphragmatic hernia was made by Sennetus in 154, describing the late herniation of the stomach through the diaphragmatic injury of the patient.<sup>[2,3]</sup> The diaphragmatic injury is delayed when the diagnosis is performed one week after the time of injury<sup>[6,7]</sup>.

It is difficult to accurately establish the incidence of traumatic diaphragmatic

injury, with an estimated incidence of 3% of such injuries following abdominal trauma<sup>[8,9]</sup>.

In literature, for victims with penetrating injuries in thoracic and/or abdominal region, the incidence of injury to the diaphragm varies between 10 and 15%, while in closed traumas it ranges from 0.8 to 7%<sup>[10,11]</sup>. However, the incidence of diaphragmatic rupture is greater in closed trauma, as it involves more energy dissipation and therefore the

damage to the diaphragm is greater extent. Clinical experience shows that diaphragmatic lesion by penetrating trauma are usually more than grade III AATS classification, whereas blunt trauma usually causes injury of grade IV or V. The incidence of left side traumatic diaphragmatic rupture (TDR) was significantly greater (75%).

This confirms data from literature on the prevalence of a left diaphragm injury in hospitalized patients, while autopsied victims display predominance on the right (12) Aun et al.<sup>[12]</sup>, observed a significantly higher incidence of diaphragmatic lacerations on the right in the autopsy group (49.6 % of 146 cases identified in 12,276 autopsies).

Pain in the upper abdomen and lower thorax, dyspnea, cyanosis and hypotension are typical symptoms of diaphragmatic injury. These symptoms may be masked by concomitant severe injuries to other organs, in case of small tear and no herniation, specific signs and symptoms may not be present during the acute phase. With larger lesions and herniation of the abdominal contents, breath sounds decrease and bowel sounds may be heard over the lower thorax. With massive herniation there will be signs of a mediastinal shift to the opposite site. Such situation can be observed after some weeks or months from the moment of trauma<sup>[13]</sup>.

Preoperative diagnosis of traumatic injury to the diaphragm is difficult<sup>[14]</sup>. To diagnose, a high index of suspicion is required. Although the first chest X-ray frequently suggests only a raise of the diaphragm or hemothorax, the surgeon should be alert to the possibility of rupture. Gas densities above the usual diaphragm level, along with adjacent plate-like atelectasis, are strong indication of diaphragmatic rupture.

A review of literature demonstrates that CXR suggests the diagnosis of less than 40% of cases of diaphragmatic injury, despite it being the mostly requested imaging method after the initial occurrence

of trauma<sup>[11,13,14,15]</sup>. After introduction of contrast by nasogastric or orogastric, increase the sensitivity of the test to the level of 50%<sup>[11,16,17]</sup>. The examination was performed, since the CXR brought doubts about the presence of (TDR).

Actually helical C-T scan with axial, sagittal and coronal reformed is reported to reach a sensitivity of 50% and 78% in diagnosing right and left-sided diaphragmatic injuries respectively<sup>[18,19]</sup>.

Finally, MRI presents a high sensitivity in the study of the (TDR) shows diaphragmatic defects and intrathoracic herniation. However this technique cannot be performed in emergency situations or multitrauma patients<sup>[20,21]</sup>.

The use of ultrasound for the diagnosis of the lesion of the diaphragm has been reported, but the method is limited by subcutaneous emphysema, the chest wall, thickness of the abdominal wall and the presence of gas in the stomach<sup>[22,23]</sup>. In most published studies, the organ mostly herniated was the stomach, which was occurred by this study, occurring in 10-cases (26.3%), followed in decreasing frequency, by following organs spleen, bowel, kidney, liver.

TDR usually require early surgical treatment so that intestinal obstruction, strangulation and cardio-respiratory embarrassment are involved, are avoided<sup>[24]</sup>. A patient's prognosis depends on the size of the hernia and extent of damage to the affected organs in chronic cases. These injuries can repaired using a Trans-thoracic or Trans-abdominal approach, typically non-absorbable sutures, large defect using Teflon patch graft.

Some reports have supported the role of video assisted thoracoscopic surgery (VATS). In management of (TDR), with a sensitivity and specificity of 100% being quoted<sup>[25]</sup>. We fell that VATS is best reserved for stable patients when intra-abdominal and contra-lateral diaphragmatic injuries are excluded. Laparoscopy is used to evaluate abdominal trauma and

reduces the number of unnecessary laparotomies. Laparoscopy is commonly used to repair diaphragmatic rupture [26,27,28,29]. Treatment of choice is mainly based on the clinical situation therefore the timing of these procedures should be in accordance with the hemodynamic and respiratory status of the patient.

Surgical repair is necessary, even for small tears, because the defect will not heal spontaneously. The parieto-peritoneal pressure gradients favor enlargement of the defect with herniation of abdominal contents.

The choice of surgical approach includes thoracotomy, laparotomy, or both if necessary. A laparotomy is recommended for patients' diagnosed early, allowing exploration of the abdominal organs for associated injuries. Thoracotomy is necessary for isolated diaphragmatic rupture and late case.

The prognosis is generally good with immediate repair. Minimally invasive techniques for diaphragmatic repair are becoming more common than before. With advances in technology and surgical skills, repairing both acute and chronic TDR is possible with laparoscopic, thoracoscopic, or combined approaches [30].

The post-operative morbidity and mortality was observed 16-cases (41.9 %). And mortality was 3-cases (7.8 %) due to irreversible shock.

### Conclusion:

Early diagnosis and treatment are similar regardless of the mechanism of trauma; this will reduce intra and post-operative morbidity and mortality in traumatic diaphragmatic rupture.

### References:

- 1- Noon, G. P.; Bcall, A. C. and Jr, DeBakey M. E. Surgical management of traumatic rupture of the diaphragm Trauma 1966.Vol. 6 Pp: 344-352.
- 2- Payne, J. H. J. r. and Yellin, A. E. Traumatic diaphragmatic hernia. Arch Surg 1982. Vol. 117. Pp: 18-24.

- 3- Carter, B. N.; ,Giuseffi, J. and Felson B. Traumatic diaphragmatic hernia. Am J Roentgenol 1951. Vol. 65. Pp: 56-72
- 4- Milhos, P.; Potaris, K. and Gakidis, Traumatic rupture of the diaphragm: experience with 65 patients. Injury 2003.Vol. 3 Pp: 169-72.
- 5- Shah, R.; Sabanathan, S. and Mearns, A. J. Trauma tic rupture of the diaphragm. Ann Thorac Surg 1995. Vol. 60. Pp: 1444-9.
- 6- Hegarty, M. M.; Bryer, J. V. and Angorn, I. B. Delayed presentation of traumatic diaphragmatic hernia. Ann Surg 1978. Vol. 188. Pp: 229-233.
- 7- Falcone, R. E.; Barnes, F. E. and Hoogeboom, J. E. Blunt diaphragmatic rupture diagnosed by laparoscopy: Report of a case. J. Laparosc.Surg 1991.Vol. 1. Pp: 299-302.
- 8- Feliciano, D. V.; Mattox, K. L.; Moore, E. F. and (Eds), Trauma, McGraw-Hill, 2008.
- 9- Young, R. L.; Page, A. J. and Cooper N. J. Sensory and motor innervation of the crural diaphragm by vagus nerves. Gastroenterology 2010. Vol. 138. Pp: 1091.
- 10- Hanna, W. C.; Ferri, L. E.; Fata, P. Razek, T. and Mulder, D. S. The current status of traumatic diaphragmatic injury: Lessons learned from 105 patients over 13 years. Ann Thorac Surg. Mar. 2008. Vol. 85 (3) Pp: 1044-8.
- 11- Bodanapally, U. K.; Shanmuganathan, K, Mirvis, S. E. I. MDCT diagnosis of penetrating diaphragm injury. Eur Radiol 2009. Vol. 19. Pp: 1875.
- 12- Aun, F.; Lourencao, J. L.; Younes, R. N.; Alfieri Junior, F.; Birolini, D. and Oliveira, M. R. Contribuicao ao estudo da historia natural e dos fatores de risco das hernias diafragmaticas. Rev Clin Fac Med Univ Sao Paulo. 1982. 37. (6). Pp: 265-70.
- 13- Beltrami, V.; Mucill, M. and Di Nuzzo, D. Post-traumatic diaphragmatic hernia. Second world

- week of professional updating in surgery and in surgical and oncological disciplines of the University of Milan. Lecture Book. Monduzzi Editore. Milano,1990. Pp: 138-40.
- 14- Gelman, R.; Mirvis, S. E. and Gens D. Diaphragmatic rupture due to blunt trauma. *A J R Am J Roentgenol.* 1991. Vol. 156 (1) Pp: 51-7.
  - 15- Sandrine, L.; Thomas, L.; Frederic W. Hugues, S.; Gilles, G. and Alain G. Imaging of Diaphragm injury: A Diagnostic Challenge. *Radiology.* 2013. Vol. 1. Pp: 121- 260.
  - 16- Bhavnagri, S. J. and Mohammed, T. L. When and how to image a suspected broken rib. *Cleve Clin J Med.* 2009. Vol.76. Pp: 309.
  - 17- Stein, D. M.; York, G. B. and Boswell, S. Accuracy of computed tomography (CT) scan in detection of penetrating diaphragm injury *Trauma* 2007.Vol. 63 Pp: 538.
  - 18- Iochum, S.; Ludig, T. and Walter, F. Imaging of diaphragmatic injury. *Radio-graphic* 2002. Vol. 22. Pp: 103.
  - 19- Shanmuganathan, K.; Mirvis, S. E.; White, C. S. and Pomerantz, S. M. M. R. Imaging evaluation of hemidiaphragms in acute blunt trauma: experience with 16 patients. *A J R Am J Roentgenol* 1996. Vol. 167. Pp: 397.
  - 20- Bocchini, G.; Guida, F.; Sica, G.; Codella, U. and Scaglione, M. Diaphragmatic injuries after blunt trauma: are they still a challenge Reviewing CT findings and integrated imaging. *Emerg Radiol.* Jun 2012. Vol. 19 (3) Pp: 225-35.
  - 21- Blaivas, M.; Brannam, L. and Hawkins M. Beside emergency ultrasonographic diagnosis of diaphragmatic rupture in blunt abdominal trauma. *Am J Emerg Med* 2004. Vol. 22. Pp: 601.
  - 22- Eren, S. and Ciris, F. Diaphragmatic hernia: diagnostic approaches with review of the literature. *Eur J Radiol.* 2005. Vol. 54 (3) Pp: 448-59.
  - 23- Ammann, A. M.; Brewer, W. H.; Manull K. I. and Walsh, J. W. Traumatic rupture of diaphragm: real time sonographic diagnosis. *A J R Am J Roentgenol.* 1983. Vol.140 (5) Pp: 915-6.
  - 24- Mihos, P.; Potaris, K. and Gakidis Traumatic rupture of the diaphragm: experience with 65 patients. *Injury* 2003.Vol. 3 Pp: 169-72.
  - 25- Mintz, Y.; Easter, D. W. and Izhar, U. Minimally invasive procedures for diagnosis of traumatic right diaphragm tears: a method for correct diagnosis in selected patients. *Am Surg* 2007. Vol. 73 Pp: 388-92.
  - 26- Ahmed, N.; Whelan, J.; Brownlee, J.; Chari, V. and Chung, R. The contribution of laparoscopy in evaluation of penetrating abdominal wounds. *J Am Coll Surg* 2005. Vol. 201 Pp: 213-6.
  - 27- Campos, L. I. and Sipes, E. K. Laparoscopic repair of diaphragmatic hernia. *J Laparoendosc Surg.* 1991. Vol.1 (6) Pp: 369-73.
  - 28- Friese, R. S.; Coln, C. E. and Gentilello, L. M. Laparoscopy is sufficient to exclude occult diaphragm injury after penetrating abdominal trauma. *J. Trauma* 2005. Vol. 58. Pp: 789.
  - 29- Livingston, D. H.; Tortella, B. J. and Blackwood, J. I. The role of laparoscopy in abdominal trauma. *J Trauma* 1992. Vol. 33. Pp: 471-475.
  - 30- Zarour, A. M.; EL-Menyar, A.; Al-Thani, H.; Scalea, T. M. and Chiu, W. C. Presentations and outcomes in patients with traumatic diaphragmatic injury: a 15-year experience *Trauma Acute Care Surg.* Jun 2013.Vol. 74 (6) Pp: 1392-8.