

Vascular Endothelial Growth Factor (VEGF-C) Protein Expression Related with Lymphangiogenesis in Iraqi Cervical Cancer Patients

Yasser kadhim Hashem Al-Zwaini*, Wassan Abdul Kareem Abbas**, Sahira Hamdan Abbas_Alzubaidi***, Azza Nazar Dhannoon Aljaleeli***, Suhad Faisal Hatem Al-Mugdadi**

*Al-Israa university/ Iraq

** Mustansiriyah University/ College Of Pharmacy/Department of Clinical Laboratories sciences /Iraq

***Baghdad medical city /Pathology Department/ Iraq.

DOI: <https://doi.org/10.32947/ajps.19.04.0416>

Article Info:

Received 8 Jul 2019

Accepted 11 Sep 2019

Published 1 Nov 2019

Corresponding Author email:

Yasser_alzwaini@yahoo.com

orcid: <https://orcid.org/0000-0002-7164-7093>

Abstract:

Objective: Metastatic spread of tumor cells to distant organs is the leading cause of mortality from cancer. Although metastatic tumor spread can occur via a different mechanism. lymphangiogenic factors recognized were vascular endothelial growth factor (VEGF)–C and –D, which bind to a tyrosine kinase

receptor, VEGF receptor (R)–3. Binding affinities to VEGFR-2 receptor increase on the lymphatic and blood endothelium therefore enables both growth factors to also exert lymphangiogenic and angiogenic effects and increased incidence of lymph node metastasis. The aim of this study is to evaluate the VEGF-C protein expression in cervical cancer cells and lymph vessels and found the relationship of this marker with lymphangiogenesis of Iraqi cervical cancer samples.

Method: In this study, expression of VEGF-C was noticed in 55 cervical samples by Immunohistochemistry. 35 cases diagnosed as invasive cervical cancer in addition to 20 normal samples consider as control. Immunohistochemistry was performed and the cytoplasm level of VEGF-C was scored by the percentage of positive cells and intensity.

Results:

The present data evaluated the prognostic significance of VEGF-C to cervical cancer, cytoplasm staining was seen in 29 cases (82.9 %) in cervical cancer tissues. Only 4 out of 35 cases (11.4 %) displayed cytoplasmic and nuclear tissue. There is significant difference of VEGF-C staining in lymphatic vessels and cancer cells ($\chi^2= 5.04$, $p = 0.023^*$) regarding to positive expression (20/ 57.1%), (25/ 71.4 %) respectively and negative VEGF-C staining 15 (42.9%), 10 (28.6 %) respectively. High positive percentage of VEGF-C expression in cytoplasm of malignant cases in score 2& 3 (25.7%, 45.7 %, $P\text{-value}= 0.0392^*$, 0.029^* respectively) as compared to normal cases (15%, 30% respectively). Demographic criteria of patients revealed association with VEGF-C expression patterns. Differentiation Well + moderately and histologic type Squamous carcinoma showed significantly associated with VEGF-C ($P=0.0071^{**}$ & 0.0071^{**} respectively). Positive VEGF-C staining in cancer cells had more lymphatic vessel (17/68 %) as compared to negative cases (3/30 %) with Chi-Square 8.263, $p\text{ value}= 0.0061^{**}$. Also, positive VEGF-C staining had more lymph node associated (9/36%) compared to negative cases (1/10 %) with Chi-Square 13.503, $p\text{ value}= 0.0001^{**}$.

Conclusion:

In conclusion, high expression of vascular endothelial growth factor was noticed in cervical cancer cells and lymph vascular invasion indicating the important role of this marker as prognostic factor for Iraqi cervical cancer. Additionally, these results suggested that VEGF-C promoted cervical cancer metastasis using immunohistochemistry technique. Our findings offer new vision into the role of VEGF-C in cervical cancer development and give potential target for study the lymphangiogenesis of tumor in Iraqi women.

Key words: VEGF-C marker, cervical cancer, IHC, cytoplasm expression, Lymph vascular, lymph node

التعبير البروتيني لعامل نمو بطانة الأوعية الدموية (VEGF-C) بتولد الاوعية اللمفية في سرطان عنق الرحم لمرضى عراقيين.

ياسر كاظم هاشم الزويني*, وسن عبد الكريم **, ساهرة حمدان عباس***, عزة نزار دهنون***, سهاد فيصل حاتم**

*كلية الاسراء الجامعة

**الجامعة المستنصرية / كلية الصيدلة / قسم العلوم المختبرية السريرية

***مدينة الطب

الخلاصة:

الموضوع: انتشار الخلايا السرطانية الى الاعضاء البعيدة هو السبب الرئيسي للوفاة من السرطان ، انتشار الورم يمكن ان يحدث عن طريق اليات مختلفة ، احد العوامل للمفاوية المعترف بها هو عامل نمو بطانة الاوعية الدموية والذي يرتبط بمستقبلات تايروسين كابينز VEGF-C and -D ومستقبلات في اي جي اف ار-3.

ان قدرة الارتباط بمستقبلات في اي جي اف ار ٢- والتي تزداد ببطانة الانسجة للمفاوية و الدم تساهم بزيادة حدوث ورم خبيث للعقد للمفاوية . هدفت هذه الدراسة الى تقييم تعبير بروتين في اي جي اف - سي في خلايا سرطان عنق الرحم و الاوعية للمفاوية في نسيج مرضى عراقيين

الطريقة : في هذه التجربة , لوحظ التعبير لل في اي جي اف - سي في ٥٥ عينة من عنق الرحم بواسطة الطريقة الكيميائية النسيجية المناعية ، حيث ان ٣٥ حالة تم تشخيصها على انها سرطان عنق الرحم الخبيث بالإضافة الى ٢٠ عينة لاثوي سرطان تعتبر كسيطره، ثم تم اجراء التقييم الكيميائي النسيجي المناعي وتم تقييم مستوى تعبير في اي جي اف - سي في الساييتو بلازم الخلايا كنسبة مئوية وشدة الصبغة.

النتائج : اظهرت النتائج في البيانات الحالية تقييم اهمية الفي اي جي اف - سي لسرطان عنق الرحم ، شوهد تصبغ الساييتوبلازم في ٢٩ حالة وبنسبة (٨٢,٩ %) في انسجة سرطان عنق الرحم . فقط ٤ من اصل ٣٥ حالة بنسبة (١١,٤٪) ظهرت الصبغة في الساييتوبلازم و النواة . هناك اختلاف معنوي كبير في تصبغ هذا الماركر في الاوعية للمفاوية و الخلايا السرطانية فيما يتعلق بالعينات الموجبه (٥٧,١ / ٢٠)٪ ، (٧١,٤ / ٢٥)٪ على التوالي و العينات السالبة لهذا الماركر (١٥ / ٤٢,٩)٪ ، (٢٨,٦ / ١٠)٪ على التوالي . هناك نسبة ايجابية عالية من التعبير في اي جي اف - سي في الساييتو بلازم في العينات السرطانية في مستوى التعبير ٢ و ٣ (٢٥,٧٪ ، ٤٥,٧ % على التوالي مقارنة مع العينات غير السرطانية. * 0.0392, P-value= ٠,٠٢٩ *

دراسة المعايير الديموغرافية للمرضى اظهرت وجود ارتباط مع تعبير الفي اي جي اف - سي حيث ظهرت فروق معنويه بما يخص التمايز ونوع السرطان. كان تصبغ الفي اي جي اف - سي في الخلايا السرطانية (٦٨٪ / ١٧) اعلى في العينات الحاويه على الاوعية للمفاوية مقارنة مع الحالات السالبة (٣٠٪ / ٣) ، كذلك كان تصبغ في اي جي اف - سي اعلى في العينات الحاوية على العقد للمفاوية (٣٦٪ / ٩) مقارنة مع الحالات السالبة (١٠٪ / ١) .

الاستنتاج: لوحظ ان ارتفاع تعبير عامل نمو بطانة الاوعية الدموية في خلايا سرطان عنق الرحم و نمو الاوعية اللمفي ، مما يدل على الدور الهام للماركر كعامل تنبأ لسرطان عنق الرحم في المرضى العراقيين . بالإضافة الى ذلك ، اقترحت هذه النتائج ان ال في اي جي اف - سي يحفز انتشار الورم في سرطان عنق الرحم باستخدام التقنية الكيميائية النسيجية المناعية ، كذلك قدمت الدراسة الحالية رؤيا جديدة لدور هذا الماركر في تطور سرطان عنق الرحم و تعطي هدفا محتملا فتح افاق دراسة تولد الاوعية اللمفية لدى النساء العراقيات.

الكلمات المفتاحية: البروتين في اي جي اف - سي، سرطان عنق الرحم ، التقنية الكيميائية النسيجية المناعية، التعبير الساييتوبلازمي، الاوعية للمفاوية، العقد للمفاوية.

Introduction

Cervical cancer is one of the most common malignancy world-wide and it remains the important cause of death especially for women in developing countries (1). The main reason for cervical cancer mortality is the metastasis of cancer cells to distant tissues and organs (2). A number of growth factors and their cognate receptors have been stated to regulate cervical cancer invasion and metastasis (3). Thus, disturbance of these growth factors and receptor axis is a recent strategy for the treatment of cervical cancer.

Because of the comparatively low incidence of cervical cancer among women worldwide and high prevalence of HPV infection, certain cofactors have been involved in the development of cervical cancer (4). These cofactors comprise, but are not restricted to, smoking tobacco, high parity (number of children), long-term hormonal contraceptive use, and coinfection with the human immunodeficiency virus (HIV) (5).

Other possible cofactors include immunosuppression, and coinfection with Chlamydia trachomatis or herpes simplex virus-2 (HSV-2), among other nutritional and hereditary factors (4-6).

Metastatic spread of tumor cells to distant organs is the leading cause of mortality from cancer (7). Although metastatic tumor spread can occur via a different mechanism including direct local invasion of tissue or the seeding of body cavities, most metastases arise following invasion of and dissemination via the circulatory systems. Whereas both the blood and lymphatic vascular systems have been involved, preclinical experimental systems supported by clinical evidence suggest the most common pathway of initial metastasis is through the lymphatic system. (8, 9)

Vascular endothelial growth factor (VEGF), originally known as vascular permeability factor (VPF) is a signal protein produced by cells that encourages

the formation of blood vessels. It is significant signaling proteins involved in both vasculogenesis (formation of the embryonic circulatory system) and angiogenesis (the growth of blood vessels from pre-existing vasculature) (10).

When VEGF is overexpressed, it can contribute to disease. Solid cancers cannot grow beyond a limited size without sufficient blood supply; cancers that can express VEGF are able to grow and metastasize.

Invasive tumor cells can deed the loose, overlapping endothelial cell junctions and incomplete basement membrane of lymphatic capillaries to take advantage of the transport network that is highly open to cell survival. It has become apparent that lymphangiogenesis, the generation of new lymphatic vessels contribute to tumor metastasis (11-13).

The first, and most comprehensively studied, prolymphangiogenic factors recognized were vascular endothelial growth factor (VEGF)-C and -D, which bind to a tyrosine kinase receptor, VEGF receptor (R)-3, expressed on the lymphatic endothelium (14-17), also binding affinities to VEGFR-2 receptor increase on the lymphatic and blood endothelium therefore enables both growth factors to also exert lymphangiogenic and angiogenic effects (18, 19) and increased incidence of lymph node metastasis (20-22).

Many studies about the function of lymphangiogenic factors in human cancer metastasis were investigated by immunohistochemical methode of tumor tissue samples and compared to many parameters (23-25). In this study, VEGF-C protein was valued as marker to detect patterns of expression in lymphatic vessels and cancer cells in cervical cancer samples and explain the associated this marker with many clinical parameters linked with lymphangiogenesis.

Method

Patients and tissue samples

A total of 55 cervical tissue samples divided into 35 malignant and 20 normal were collected between September 2018 to March 2019 from / teaching laboratories, Baghdad Medical City. In these samples, 32 cases were squamous cell carcinoma and 3 cases were adenocarcinoma. In cervical cancer, 10 cases had lymph node metastasis. The study was agreed by Mustansiriyah University / College of Pharmacy.

Immunohistochemistry staining of VEGF-C

All tissue paraffin embedded sections (4mm) were submitted to deparaffinized; rehydrated and target retrieval solution/Dako (pH 9.0). To detect protein expression of VEGF-C, MyBioSource /USA IHC staining kit was used in relative to the manufacturer's instructions method. The sections were detected with primary polyclonal antibody for VEGF-C (1:200 dilution; MyBioSource, USA) without washing at 4°C for 6 hours, Two drops from secondary antibody **poly- HRP Goat Anti-Rabbit IgG** was applied and incubated for 1 hour, sections treated with **DAB working solution** then hematoxylin and mounted. Finally, all the microarrays (thin-tissue cores as small as 0.6 mm in diameter) sections were examined and photographed with a light microscope.

Scoring Analysis

All immune-staining slides were examined under 10X, 40X, 100X using light microscope by two pathologists (Dr. Sahira Hamdan Abbas and Azza Nazar Dhannoon). The number and percentage of positive cervical cells for VEGF-C localized cytoplasm calculated manually in

5 (HPFs magnification, x40) described by Tang J.*et al.* (2017). Protein expression of this marker divided to 4 score includes score 0 (no staining in tumor cells); score 1⁺ (weak staining < 10% of tumor cells); score 2⁺ (moderate staining 10-50 % of tumor cells); and score 3⁺ (strong staining > 50 % of tumor cells). Score 2+&3+ was considered as positive cervical cells expression. While expression in lymph vessels scored accordance to the intensity to negative staining, low, moderate and high or strong staining in relative to deep of brown color of this marker (26).

Statistics

Statistical significance was revealed with by SAS (2012) program which used to identify the effect of difference factors in study parameters. Chi-square test was used to significant compare between percentages, P-value 0.05 consider significant and 0.01 consider highly significant (27).

Results:

VEGF-C expression in cervical cancer and normal cervical tissues

According to the Fig (1), Fig (2a, b) and Fig (3a, b), cytoplasm staining was of VEGF-C seen in 29 cases (82.9 %) out of 35 cervical cancer samples. Only 4 out of 35 samples (11.4 %) displayed cytoplasmic and nuclear staining together. In addition out of 20 normal cervical tissues, 11 (55 %) samples showed cytoplasm staining in the epithelium of cervical tissue while there was 1 (5 %) case with cytoplasmic and nuclear together as shown in Fig (3a, b). There is greatly significant difference of the VEGF-C expression in malignant and normal (0.0072**).

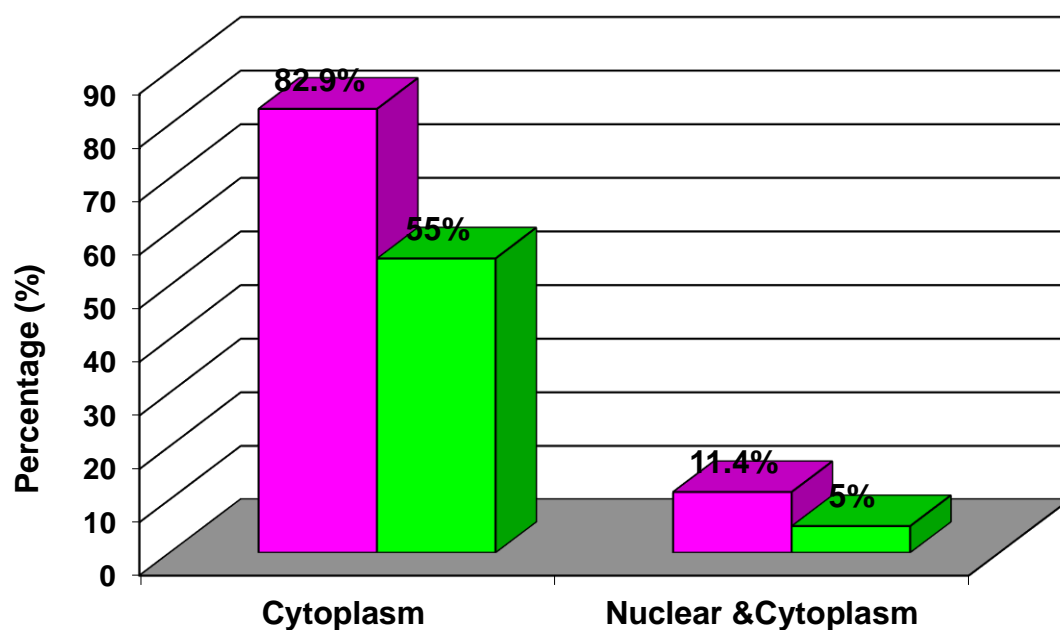
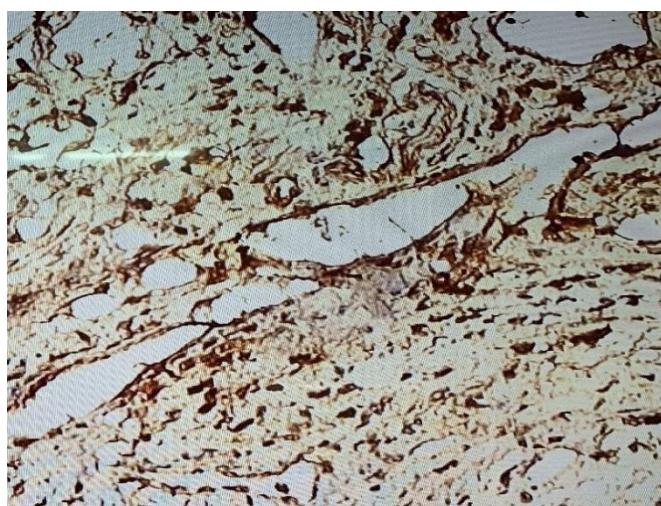
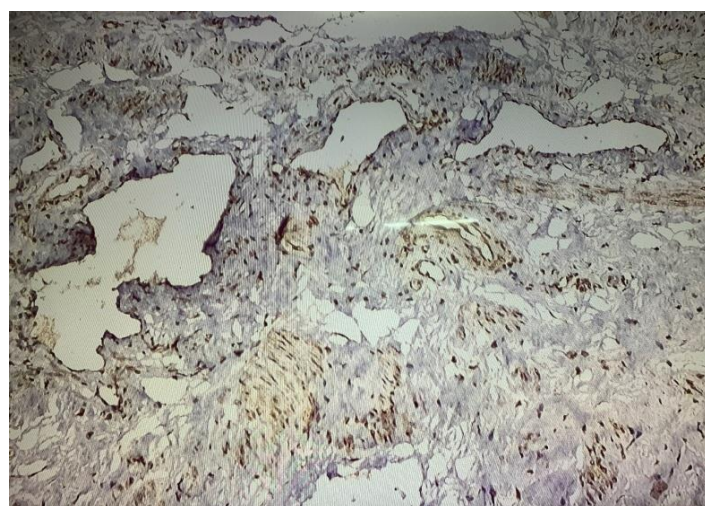


Figure 1: Positive Samples cytoplasm and cytoplasmic - nuclear VEGF-C expression in cervical cancer and normal samples using IHC.

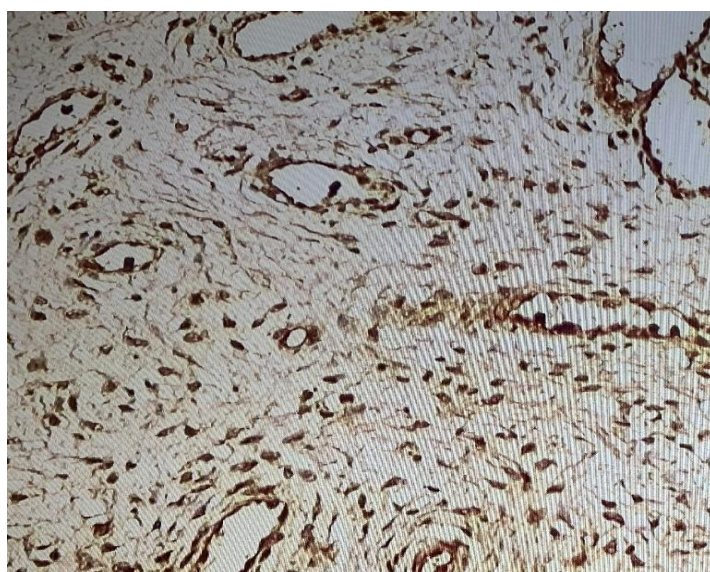


(A)

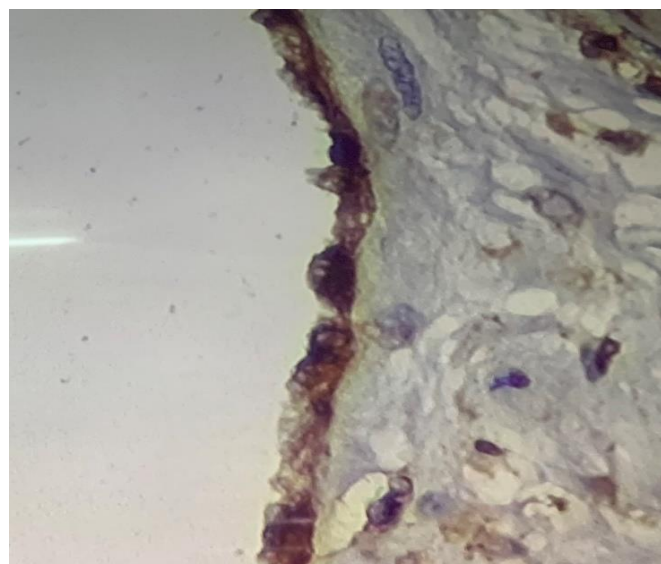


(B)

Figure 2: A: Section of squamous carcinoma stained with anti VEGF-C antibody showing nuclear and cytoplasmic localization of VEGF-C in cancer cells. B: stained with anti VEGF-C antibody showing cytoplasm localization of VEGF-C in cancer cells by using IHC Technique (40X).



(A)



(B)

Figure 3: A: section of Normal cells stained with anti VEGF-C antibody showing nuclear and cytoplasmic localization of VEGF-C in normal cells. B: stained with anti VEGF-C antibody showing cytoplasm localization of VEGF-C in normal cells by using IHC Technique (40X).

Cytoplasm VEGF-C expression in cervical cancer and normal samples according to the score.

Because of the cytoplasmic expression predominant, the results cited according to it. High positive percentage of malignant cells cases in cytoplasm VEGF-C expression in score 2& 3 (25.7%, 45.7 %, P-value=0.0392*, 0.029*correspondingly)

compared to normal cases (30%, 15%). Whereas the results in score 1 revealed no significant differences in malignant and normal cases. 8 (40%) cases only among 20 cases of normal samples revealed no expression of cytoplasm VEGF-C, score 0&1 considered negative as summarized Fig (4).

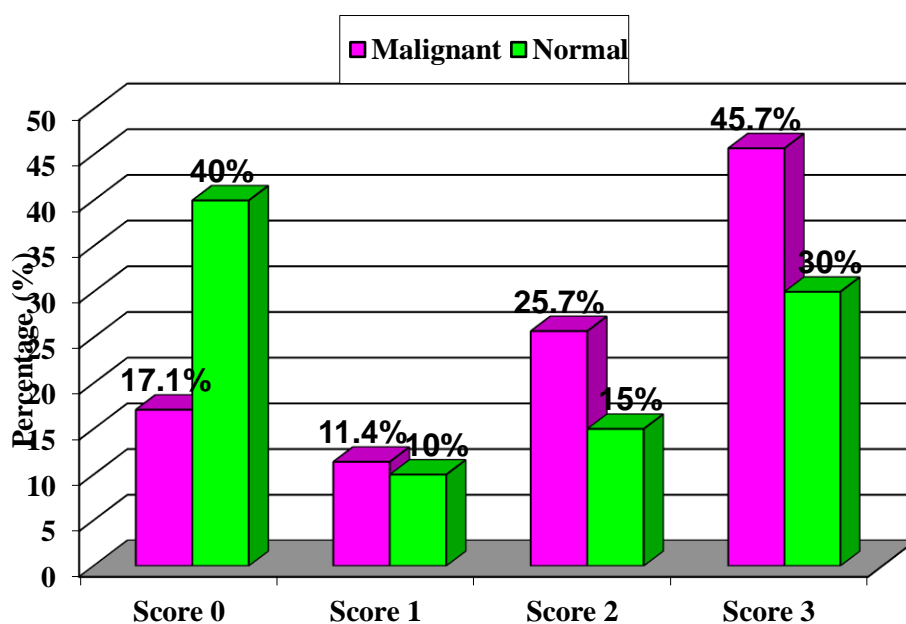


Figure 4: Distribution of positive cytoplasm VEGF-C expression in cervical cancer cells according to the score

VEGF-C expression in lymph vessels and cervical cancer cells.

Figure (5) showed There is significant difference of VEGF-C staining in lymphatic vessels and cancer cells ($\chi^2 =$

5.04, $p = 0.023^*$) regarding to positive expression (20/ 57.1%), (25/ 71.4 %) respectively and negative VEGF-C staining 15 (42.9%), 10 (28.6 %) respectively.

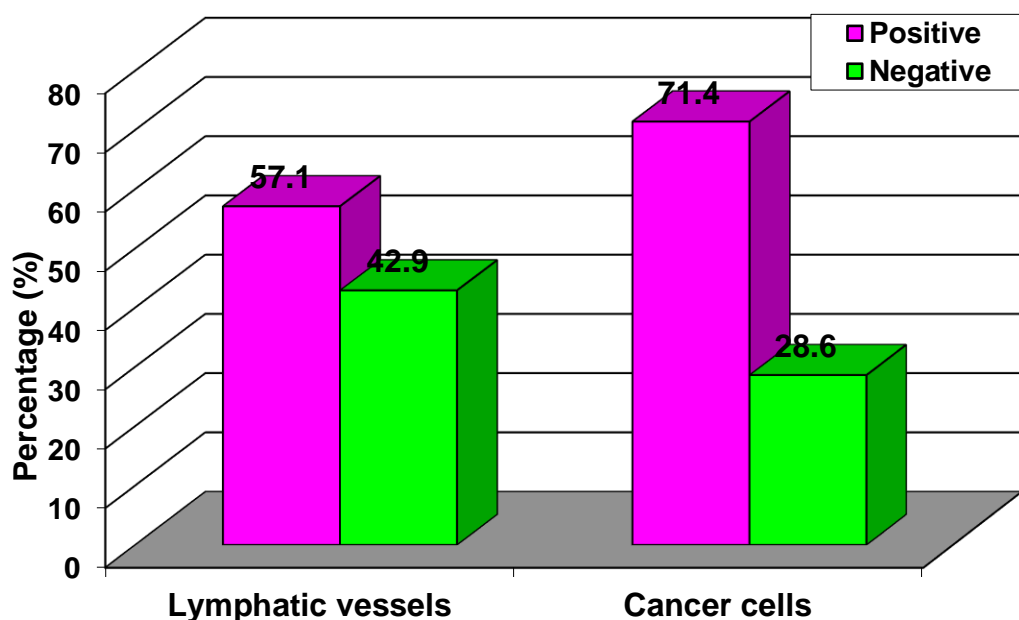


Figure 5: Number and percentage of positive VEGF-C immune reactive associated with lymph vessels and cervical cancer samples using IHC

Association between VEGF-C Expression and Clinic pathologic Parameters of cervical tumor.

The percentage of positive tumor cells to this marker varied among samples, therefore analysis of IHC data of VEGF-C related with some clinic pathologic parameters were achieved by scoring the percentage of positive tumor cells with cytoplasm staining and categorized to negative and positive expression. The VEGF-C Positive expression group was 25 cases (71.4%) including score 2&3, whereas VEGF-C negative expression group was 10 cases (28.6 %) including score 0&1 from the total number (35) of malignant samples.

According to the data summarized in Table (1), demographic criteria of patients

revealed association with VEGF-C expression patterns. Differentiation Well + moderately and histological type Squamous carcinoma showed significant difference ($P=0.0071^{**}$ & 0.0071^{**} respectively) between the positive and negative cytoplasm VEGF-C expression while no difference regarding to the age. Cases with positive VEGF-C staining had more lymphatic vessel (17/68%) compared to cases negative VEGF-C expression (3/30 %) with Chi-Square 8.263, p value= 0.0061 ** . Similarly, VEGF-C positive staining related with lymph node existence group 9(36%) compared to negative expression group (0%) with P-value=0.0001 ** , as mention in Fig(6)&(7).

Table 1: Clinic pathological parameters associated with positive cytoplasm VEGF-C expression in cervical cancer cells samples
HS: Highly significant at $p < 0.01$, S: significant at $p < 0.05$

Clinical parameters		Negative expression =10	Positive expression=20	Chi-Square (χ^2)	P-value
Variable	NO.	No (%)	No (%)		
Age (year)					
> 50	10	5 (36.4)	5 (31.0)	2.071 NS	0.0933
≤ 50	25	5 (60)	20 (68.9)		
Differentiation + moderately 31 poorly	4	1 (70) 3 (30)	3 (93.1) 1 (6.9)	7.884 **	0.0071
Histological type Squamous carcinoma Adenocarcinoma	32 3	1 (100) 0	2 (88) 3 (12)	4.528 *	0.0071
Lymph vascular invasion Yes: No:	20 15	3 (30) 1 (70)	1 (68) 1 (32)	8.263 **	0.0061
Well Lymph node metastases Yes: No:	10 25	1 (10) 9 (90)	9 (36) 16 (64)	13.503 **	0.0001

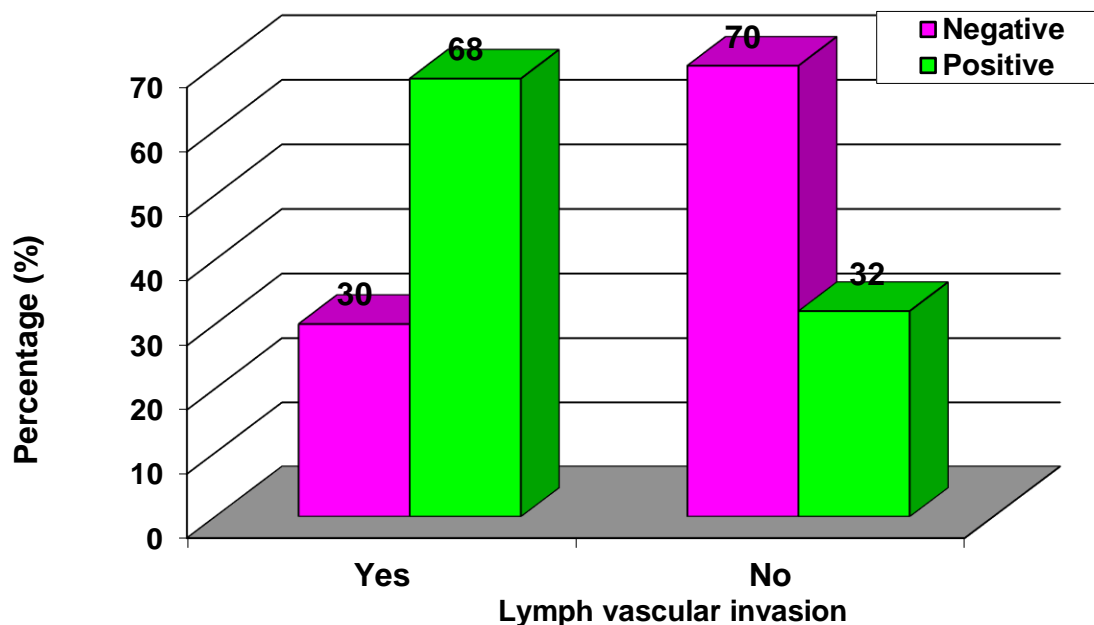


Figure 6: Positive cytoplasm VEGF-C expression in cervical cancer cells associated with lymph vascular invasion samples

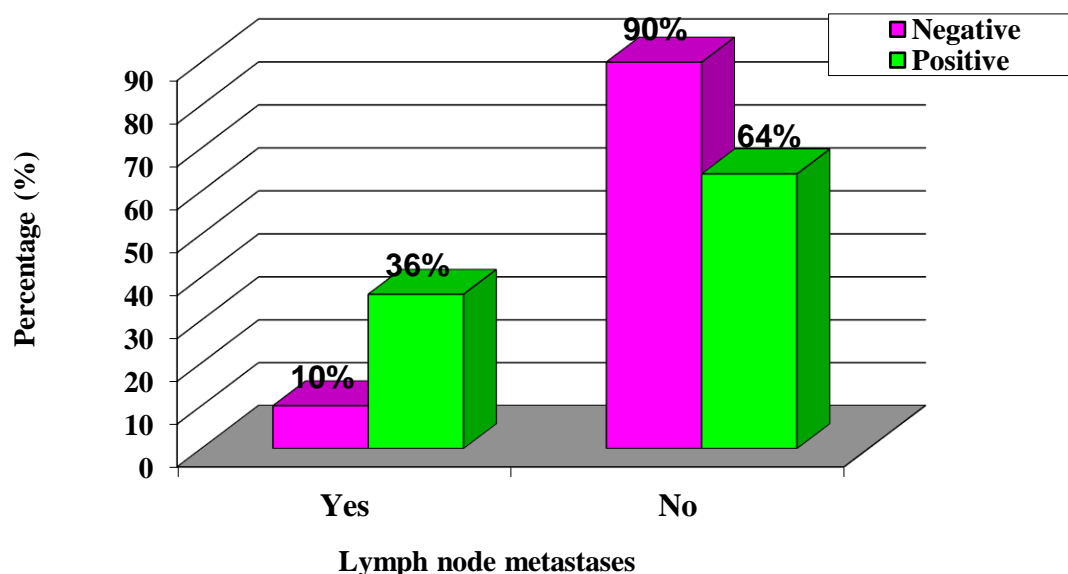


Figure 7: Positive cytoplasm VEGF-C expression in cervical cancer cells associated with lymph node metastases samples

Discussion:

Cervical cancer is one of the most frequent types of tumor worldwide and its metastasis is the leading cause of death in patients with cervical cancer. On the other hand, the current understanding on the mechanisms of cervical cancer metastasis is unclear. In this study, we demonstrated

that VEGF-C accelerated cervical cancer metastasis by directly driving cancer cell migration and invasion. In the recent study, Fig (1), Fig (2a, b) and Fig(3a,b) revealed the predominant pattern of VEGF-C expression was cytoplasm in both normal and cervical cancer cells cases. According to the expression level,

highly significant difference notated in malignant versus normal cases (0.0072**). This result agreement with Akagi K *et al.* (2000), showed VEGFC protein expression in the cytoplasm of colorectal cancer cells using, on the other hand, no expression was observed in the nucleus area by using IHC and RT-PCR. The VEGF-C mRNA expression, was high in cancer compared to normal (28). Also, other study goes in line with recent data in breast and acute myeloid leukemia (26, 29)

In the current study, Fig (4) reported the percentage of malignant and normal samples according to the score of positive VEGF-C immunohistochemical expression in cytoplasm localization in both malignant and normal epithelial cells. data shown that score 2 and score 3 was significantly high in malignant samples compared to normal. As mention above the score 2&3 considered positive expression (25/71.4%) tissue samples while score 0&1 considered negative (10/28.5 %).

Association between cytoplasm VEGF-C Expression and Clinic pathologic Parameters of cervical cancer was investigated in the recent study, Table (1) found that positive and negative expression highly significant linked with well+ moderately differentiation and Squamous carcinoma type with P value= 0.0086**, 0.0001** & 0.0001** respectively. Lymph vascular invasion and lymph node metastases in positive VEGF-C expression pattern was significant high and differ from negative expression (P value= 0.0472*, 0.0001 correspondingly) that mean related this marker with lymphangiogenesis in cervical cancer as shown in Fig (6, 7).

These results partially agreement with Jiabu T. *et al.* (2017) who noticed that immunoreactivity of VEGF-C in cervical cancer was detected in 76.0% of samples and clinic pathologic parameters according to positive and negative VEGF-C expression levels including :Age ,grade and tumor size did not

correlate with VEGF-C expression while VEGF-C expression had a significant association with cases stage and lymph node metastasis with $P < 0.05$ (26). Also, in other study VEGF was stated in 87% of oral squamous cell carcinoma specimens when compared to pre-neoplastic lesions and normal tissues. VEGF and CD105 may be considered as a good marker for tumor angiogenesis and progression in oral carcinoma but there was no correlation between VEGF expression, tumor microvascular area, clinical stage, and lymph node status (28). Whereas others (29, 30) stated a significant correlation between this marker and other clinical parameters.

This different in results may be because using different stain for diagnosis. In this study VEGF-C marker vascular detection was used which consider highly specific for lymph vascular invasion to evaluate the lymphangiogenesis of cervical cancer.

Current observations suggested that early invasive disease spreads to regional lymph nodes in several tumor types and that growth factor (VEGF-C) involved in new lymphatic vessel formation may play a crucial role in this process (31)

VEGF-C is a mitogen for lymphatic endothelial cells, and is involved in the development of lymphatic system (32,33), encouraging lymphangiogenesis and lymphatic hyperplasia (34,35), this explain many non-malignant samples consist positive VEGF-C expression. Its responsibility in mediating lymphangiogenesis is due to its ability to regulate the activation, proliferation and migration of lymphatic endothelial cells effectively to other sites. Nearby that, lymph node metastasis may happen by invasion of malignant cells into the lymphatic vessels, thus VEGF-C strongly associated with the tumor metastasis (36). Down regulation of VEGF-C expression because some decrease in the density of lymphatic structures and reduce migration ability of colon carcinoma (HCT116) and lung carcinoma (A549) cells line (40).

Furthermore, VEGF-C may stimulate microvascular endothelial cell proliferation to some area as a result of its ability to bind to VEGFR-2receptor lead to angiogenesis (37). In spite its dual receptor binding, the wild type VEGF-C effect on blood vessels is low level in several models while recent data suggested that pro VEGF-C on lymphatic epithelial cells surface prior to activation could explain this specificity (41).

Conclusion:

In conclusion, high expression of vascular endothelial growth factor was noticed in cervical cancer cells and lymph vascular invasion indicating the important role of this marker as prognostic factor for Iraqi cervical cancer. Additionally, these results suggested that VEGF-C promoted cervical cancer metastasis using immunohistochemistry technique. Our findings offer new vision into the role of VEGF-C in cervical cancer development and give potential target for study the lymphangiogenesis of tumor in Iraqi women.

Acknowledgment

The authors would like to thank Mustansiriyah University (www.uomustansiriyah.edu.iq) Baghdad / Iraq for its support in the current work.

Reference:

- 1- Sherman SM, Moss E, Redman CW. The invasive cervical cancer review: psychological issues surrounding disclosure. *Cytopathology*. 2013 Apr; 24(2):77-80.
- 2- Campbell CM, Menezes LJ, Paskett ED, Giuliano AR. Prevention of invasive cervical cancer in the United States: past, present, and future. *Cancer Epidemiology and Prevention Biomarkers*. 2012 Sep 1; 21(9):1402-8.
- 3- Tomao F, Di Tucci C, Imperiale L, Maria Boccia S, Marchetti C, Palaia I, Muzii L, Benedetti Panici P. Cervical cancer: are there potential new targets? An update on preclinical and clinical results. *Current drug targets*. 2014 Nov 1; 15(12):1107-20.
- 4- Williams WV, Mitchell LA, Carlson SK, Raviele KM. Association of Combined Estrogen–Progestogen and Progestogen-Only Contraceptives with the Development of Cancer. *The Linacre Quarterly*. 2018 Nov;85(4):412-52.
- 5- Gadducci A, Barsotti C, Cosio S, Domenici L, Riccardo Genazzani A. Smoking habit, immune suppression, oral contraceptive use, and hormone replacement therapy use and cervical carcinogenesis: a review of the literature. *Gynecological Endocrinology*. 2011 Aug 1; 27(8):597-604.
- 6- Castle PE, Xie X, Xue X, Poitras NE, Lorey TS, Kinney WK, Wentzensen N, Strickler HD, Burger EA, Schiffman M. Impact of human papillomavirus vaccination on the clinical meaning of cervical screening results. *Preventive medicine*. 2019 Jan 1; 118:44-50.
- 7- Fidler IJ, Blach CM. The biology of cancer metastasis and implications for therapy. *Current problems in surgery*. 1987 Mar 1;24(3):137-209.
- 8- Farnsworth RH, Achen MG, Stacker SA. The evolving role of lymphatics in cancer metastasis. *Current opinion in immunology*. 2018 Aug 1; 53:64-73.
- 9- Sleeman JP, Thiele W. Tumor metastasis and the lymphatic vasculature. *International Journal of Cancer*. 2009 Dec 15; 125(12):2747-56.
- 10- Baluk P, Fuxe J, Hashizume H, Romano T, Lashnits E, Butz S, Vestweber D, Corada M, Molendini C, Dejana E, McDonald DM. Functionally specialized junctions between endothelial cells of lymphatic vessels. *Journal of Experimental*

- Medicine. 2007 Oct 1;204(10):2349-62.
- 11- Lien MY, Tsai HC, Chang AC, Tsai MH, Hua CH, Wang SW, Tang CH. Chemokine CCL4 induces vascular endothelial growth factor C expression and lymphangiogenesis by miR-195-3p in oral squamous cell carcinoma. *Frontiers in immunology*. 2018 Mar 2; 9:412.
- 12- Mazzone M, Bergers G. Regulation of Blood and Lymphatic Vessels by Immune Cells in Tumors and Metastasis. *Annual review of physiology*. 2019 Feb 10; 81:535-60.
- 13- Salven P, Mustjoki S, Alitalo K, Rafii S. VEGFR-3 and CD133 identify a population of CD34+ lymphatic/vascular endothelial precursor cells. *Blood*. 2003 Jan 1;101(1):168-72.
- 14- Joukov V, Pajusola K, Kaipainen A, Chilov D, Lahtinen I, Kukk E, Saksela O, Kalkkinen N, Alitalo K. A novel vascular endothelial growth factor, VEGF-C, is a ligand for the Flt4 (VEGFR-3) and KDR (VEGFR-2) receptor tyrosine kinases. *The EMBO journal*. 1996 Jan 1;15(2):290-8.
- 15- Orlandini M, Marconcini L, Ferruzzi R, Oliviero S. Identification of a c-fos-induced gene that is related to the platelet-derived growth factor/vascular endothelial growth factor family. *Proceedings of the National Academy of Sciences*. 1996 Oct 15;93(21):11675-80.
- 16- Yamada Y, Nezu JI, Shimane M, Hirata Y. Molecular cloning of a novel vascular endothelial growth factor, VEGF-D. *Genomics*. 1997 Jun 15;42(3):483-8.
- 17- Achen MG, Jeltsch M, Kukk E, Mäkinen T, Vitali A, Wilks AF, Alitalo K, Stacker SA. Vascular endothelial growth factor D (VEGF-D) is a ligand for the tyrosine kinases VEGF receptor 2 (Flk1) and VEGF receptor 3 (Flt4). *Proceedings of the National Academy of Sciences*. 1998 Jan 20;95(2):548-53.
- 18- Cao Y, Linden P, Farnebo J, Cao R, Eriksson A, Kumar V, Qi JH, Claesson-Welsh L, Alitalo K. Vascular endothelial growth factor C induces angiogenesis in vivo. *Proceedings of the National Academy of Sciences*. 1998 Nov 24;95(24):14389-94.
- 19- Marconcini L, Marchiò S, Morbidelli L, Cartocci E, Albini A, Ziche M, Bussolino F, Oliviero S. c-fos-induced growth factor/vascular endothelial growth factor D induces angiogenesis in vivo and in vitro. *Proceedings of the National Academy of Sciences*. 1999 Aug 17;96(17):9671-6.
- 20- Hsu MC, Pan MR, Hung WC. Two Birds, One Stone: Double Hits on Tumor Growth and Lymphangiogenesis by Targeting Vascular Endothelial Growth Factor Receptor 3. *Cells*. 2019 Mar;8(3):270.
- 21- Farnsworth RH, Achen MG, Stacker SA. The evolving role of lymphatics in cancer metastasis. *Current opinion in immunology*. 2018 Aug 1; 53:64-73.
- 22- Jiang L, Liu M, Cai X, Xie L, She F, Chen Y. Serum vascular endothelial growth factor C levels predict lymph node metastasis and prognosis of patients with gallbladder cancer. *Oncology letters*. 2018 Nov 1;16(5):6065-70.
- 23- Guleria P, Srinivas V, Basannar D, Dutta V. Comparison of lymphangiogenesis, lymphatic invasion, and axillary lymph node metastasis in breast carcinoma. *Indian Journal of Pathology and Microbiology*. 2018 Apr 1;61(2):176.
- 24- Garcia-Silva S, Benito-Martin A, Nogues-Vera L, Hernandez-Barranco A, Kataru R, Merino C, Mazariegos M, Amor AI, Hergueta-Redondo M, Matei I, Mehrara B. Melanoma-derived exosomes reinforce metastasis by inducing lymphangiogenesis and

- impairing dendritic cell function. *Journal of Extracellular Vesicles*. 2018; 7:95.
- 25- Das S, Skobe M. Lymphatic vessel activation in cancer. *Annals of the New York Academy of Sciences*. 2008 May;1131(1):235-41.
- 26- Tang J, Yang Z, Wang Z, Li Z, Li H, Yin J, Deng M, Zhu W, Zeng C. Foxp3 is correlated with VEGF-C expression and lymphangiogenesis in cervical cancer. *World journal of surgical oncology*. 2017 Dec;15(1):173.
- 27- SAS. 2012. Statistical Analysis System, User's Guide. Statistical. Version 9.1th ed. SAS. Inst. Inc. Cary. N.C. USA
- 28- Miao H, Ruan S, Shen M. VEGF-C in rectal cancer tissues promotes tumor invasion and metastasis. *J Buon*. 2018 Jan 1;23(1):42-7.
- 29- Guillem V, Calabuig M, Brunet S, Esteve J, Escoda L, Gallardo D, Ribera JM, Queipo de Llano MP, Arnan M, Pedro C, Amigo ML. Bone marrow VEGFC expression is associated with multilineage dysplasia and several prognostic markers in adult acute myeloid leukemia, but not with survival. *Leukemia & lymphoma*. 2018 Oct 3;59(10):2383-93.
- 30- Mărgăritescu C, Pirici D, Stîngă A, Simionescu C, Raica M, Mogoantă L, Stepan A, Ribatti D. VEGF expression and angiogenesis in oral squamous cell carcinoma: an immunohistochemical and morphometric study. *Clinical and experimental medicine*. 2010 Dec 1;10(4):209-14.
- 31- Xue S, He L, Zhang X, Zhou J, Li F, Wang X. Expression of Jagged1/Notch3 Signaling Pathway and their Relationship with the Tumor Angiogenesis in TNBC. *Archives of medical research*. 2017 Feb 1;48(2):169-79.
- 32- Åström P, Juurikka K, Hadler-Olsen ES, Svineng G, Cervigne NK, Coletta RD, Risteli J, Kauppila JH, Skarp S, Kuttner S, Oteiza A. The interplay of matrix metalloproteinase-8, transforming growth factor- β 1 and vascular endothelial growth factor-C cooperatively contributes to the aggressiveness of oral tongue squamous cell carcinoma. *British journal of cancer*. 2017 Sep;117(7):1007.
- 33- Tang J, Yang Z, Wang Z, Li Z, Li H, Yin J, Deng M, Zhu W, Zeng C. Foxp3 is correlated with VEGF-C expression and lymphangiogenesis in cervical cancer. *World journal of surgical oncology*. 2017 Dec;15(1):173.
- 34- Kukk E, Lymboussaki A, Taira S, Kaipainen A, Jeltsch M, Joukov V, Alitalo K. VEGF-C receptor binding and pattern of expression with VEGFR-3 suggests a role in lymphatic vascular development. *Development*. 1996 Dec 1;122(12):3829-37.
- 35- Lymboussaki A, Olofsson B, Eriksson U, Alitalo K. Vascular endothelial growth factor (VEGF) and VEGF-C show overlapping binding sites in embryonic endothelia and distinct sites in differentiated adult endothelia. *Circulation research*. 1999 Nov 26;85(11):992-9.
- 36- Ribatti D. Historical overview of lymphangiogenesis. *Current opinion in immunology*. 2018 Aug 1; 53:161-6.
- 37- Jeltsch M, Kaipainen A, Joukov V, Meng X, Lakso M, Rauvala H, Swartz M, Fukumura D, Jain RK, Alitalo K. Hyperplasia of lymphatic vessels in VEGF-C transgenic mice. *Science*. 1997 May 30;276(5317):1423-5.
- 38- Joukov V, Pajusola K, Kaipainen A, Chilov D, Lahtinen I, Kukk E, Saksela O, Kalkkinen N, Alitalo K. A novel vascular endothelial growth factor, VEGF-C, is a ligand for the Flt4 (VEGFR-3) and KDR (VEGFR-2) receptor tyrosine kinases. *The EMBO journal*. 1996 Jan 1;15(2):290-8.

- 39- Cao Y, Linden P, Farnebo J, Cao R, Eriksson A, Kumar V, Qi JH, Claesson-Welsh L, Alitalo K. Vascular endothelial growth factor C induces angiogenesis in vivo. *Proceedings of the National Academy of Sciences*. 1998 Nov 24;95(24):14389-94.
- 40- Khromova N, Kopnin P, Rybko V, Kopnin BP. Downregulation of VEGF-C expression in lung and colon cancer cells decelerates tumor growth and inhibits metastasis via multiple mechanisms. *Oncogene*. 2012 Mar;31(11):1389.
- 41- Jha SK, Rauniyar K, Karpanen T, Leppänen VM, Brouillard P, Vikkula M, Alitalo K, Jeltsch M. Efficient activation of the lymphangiogenic growth factor VEGF-C requires the C-terminal domain of VEGF-C and the N-terminal domain of CCBE1. *Scientific reports*. 2017 Jul 7;7(1):4916.